

Management of Ectopia Lentis in Children

Sorath Noorani, Ayesha Khan, Shehla Rubab, Khair Ahmed Choudhary

Pak J Ophthalmol 2007, Vol. 23 No. 4

.....
See end of article for
authors affiliations

.....
Correspondence to:
Sorath Noorani
Pediatric Ophthalmologist
PCB Cell, Eye OPD,
Civil Hospital
Karachi

Purpose: To study the etiology, mode of presentation and visual outcome of ectopia lentis after lensectomy in pediatric age group.

Materials and methods: This prospective, non comparative, interventional study was conducted in the department of Pediatric Ophthalmology, Al Shifa Trust Eye Hospital, Rawalpindi, Pakistan, from November 2005 to October 2006. Fifty patients, 2.5 to 16 years of age, who presented with subluxated lenses both syndromic and non syndromic, were included in the study. Patients with secondary subluxation of lenses were excluded. Patients were selected for surgery having best corrected visual acuity 6/30 or less, pupil block glaucoma, cataract or clear subluxated lenses bisecting the pupil. Surgical technique used was within the bag lensectomy and anterior vitrectomy via limbal approach. Aphakia was treated with glasses or contact lenses followed by amblyopia treatment.

Results: Ninety six eyes of 50 patients were included in the study. Twenty six patients (52%) were male and 24 were (48%) female. All had bilateral subluxated lenses. Twelve patients (24%) had familial ectopia lentis, 11(22%) had Marfan's syndrome, 24 (48%) cases were sporadic, 2 patients (4%) had Weil Marchesani syndrome and 1 (2%) patient had suspected homocystineuria. Within the bag lensectomy was performed on 54 out of 96 eyes (56%) of 34 patients. Twenty nine (54%) out of 54 eyes had BCVA less than 6/30, 7(13%) eyes presented with pupil block glaucoma, 11 (20%) eyes had cataractous subluxated lens, 4 (7.5%) eyes had clear subluxated lenses bisecting the pupil and anterior dislocation in 3 eyes (5.5%) . Other twenty eight eyes (18 pts) out of 96 eyes were given refractive error correction and kept on follow up for progression of subluxation and intraocular pressure monitoring. Preoperatively 32 (59%) out of 54 eyes had visual acuity of hand movements to 6/60 and 22 (41%) eyes had 6/48 to 6/30. Postoperatively BCVA ranged between 6/18 to 6/15 in 29 (54%) eyes, 6/12 to 6/7.5 in 09 (17%) eyes, 6/48 to 6/24 in 5 (9%) eyes. Eleven (20%) eyes achieved 6/60 or less. Forty three (80%) out of 54 eyes showed post operative improvement in BCVA ranging from two to nine lines on ETDRS chart.

Conclusion: Within the bag lensectomy via limbal approach is a safe and effective procedure for management of ectopia lentis in pediatric age group. Aphakia corrected by glasses or contact lenses is not ideal but safer than scleral fixation of IOL and implantation of anterior chamber IOL in children.

Received for publication
July ' 2007
.....

Ectopia lentis is a condition in which the lens is displaced because of weakened or broken zonules¹. Berryat described the first reported case of lens dislocation in 1749 and Stellwag subsequently coined the term ectopia lentis in 1856¹. The lens is considered dislocated or luxated when it lies completely outside the lens pattellar fossa, in the anterior chamber, free floating in the vitreous or directly on the retina. The lens is described as subluxated when it is partially displaced but contained within the lens space. In the absence of trauma, ectopia lentis should evoke the suspicion for concomitant ocular disorder or hereditary systemic disease such as Marfan's syndrome, homocystinuria or Weil Marchesani syndrome and less commonly with hyperlysenimia and sulfite oxidase deficiency. Subluxation of a familial type or idiopathic essential ectopia lentis occurs with no other detectable ocular or systemic abnormalities². If the lens zonules have loosened uniformly, the lens will assume a spherical shape (spherophakia) and the thickened lens will induce myopia. Poor vision secondary to ectopia lentis is most commonly caused by anisometropic amblyopia, irregular astigmatism and extreme myopia (lenticular). When lens abnormality is localized to one area, astigmatism results³. Forward dislocation of the lens into the pupil or anterior chamber may cause pupil block with acute or chronic angle closure glaucoma. Dislocation into the vitreous causes intermittent blurring of vision and vitreous traction on the retina with leakage of lens proteins into the vitreous which may cause chronic vitritis and chorioretinal inflammation.

Edge of the subluxated lens transects the central pupil and distorts the retinal image. In these cases where lens prevents clear use of both phakic or aphakic portions of pupil, lensectomy is required⁴. The main purpose of this study was to evaluate the visual outcome of children with ectopia lentis in children after within the bag lensectomy surgery followed by aphakic optical correction and amblyopia treatment.

MATERIALS AND METHODS

This study was carried out at Paediatric Ophthalmology unit of Al-Shifa Trust Eye Hospital Rawalpindi from November 2005 to October 2006. A total number of 96 eyes of 50 patients ranging between the ages of 2.5 years to 16 years were included in the study. Follow up period was one month to eleven months. Secondary subluxations due to buphthalmos

or trauma were excluded. A structured questionnaire was designed to record biodata, history, presenting complaints, examination findings and investigations. Evaluation of patients included detailed history, unaided visual acuity (phakic or aphakic) using Cardiff cards, Lea symbols and ETDRS chart in an age appropriate manner, slit lamp examination, intraocular pressure with Goldmann applanation tonometer or tonopen was recorded. Dilated funduscopy was performed on all patients. Sedation with syrup trichloryl (chloral hydrate 50mg/kg body weight) was used for IOP recording and fundus examination in children under 4 years of age. Routine investigations for general anesthesia, cardiac assessment of patients with Marfan's syndrome and urine for metabolic screening to exclude homocystinuria in one patient were advised.

Within the bag lensectomy via limbal approach was the surgical technique used in this study. Pupil was dilated using, cyclopentolate 1% drops applied three times half an hour before surgery. All surgeries were performed under general anesthesia. After all aseptic measures, anterior chamber maintainer was introduced at the temporal side of limbus. A separate limbal entry wound for vitreous cutter was made. The procedure was started with circular anterior capsulotomy using the cutting mode of vitrectomy machine (vitrectorhexis) with low aspiration. The main aspect of within the bag lensectomy technique is total aspiration of nucleus and cortical material within the capsular bag. Attempts to keep the posterior and anterior capsule intact were made until the entire lenticular material was aspirated and bag was emptied. Lens capsule, zonules and the anterior vitreous were then removed using a high speed cutting mode with medium aspiration power. On completion of the procedure limbal wounds were closed with 10/0 nylon suture. Subconjunctival antibiotic and steroid combination was given. Post-operatively, topical steroids, antibiotics and cycloplegics were advised. Patients were followed postoperatively 1 day, 1 week, 4 weeks, 6 weeks and each follow up visit included IOP monitoring, best corrected visual acuity (BCVA) with glasses or contact lenses, patching treatment for amblyopia and monitoring the improvement of vision.

RESULTS

Out of 50 patients, 26 were male and 24 were female. The age of children ranged between 2.5 years to 16

years (mean 9.4 years). Table 1 represents the age of all 50 patients and Table 2 represents ages of 34 patients who had undergone lensectomy. Sporadic cases were 24 (48%), 12 patients (24%) had familial ectopia lentis, 11 patients (22%) had Marfan's syndrome, Weil Marchesani syndrome 2 patients (4%). One patient (2%) was suspected to be case of homocystinria Table 3. Out of 96 eyes lensectomy was performed on 54 eyes (56.25 %) of 34 patients, 28 eyes (29.17 %) of 18 patients having BCVA ranging from 6/24 to 6/9.5 were kept in follow-up group. Fourteen eyes (14.58 %) of nine patients were lost to follow-up. Surgical indication for within the bag lensectomy in 54 eyes were, BCVA 6/30 or less in 29 eyes (54%), pupil block glaucoma in 07 eyes (13%), cataractous subluxated lens in 11 eyes (20%), clear subluxated lens bisecting the pupil 04 eyes (7.5%), anterior dislocation 03 eyes (5.5%).

Fourteen eyes presented with glaucoma. Seven eyes with pupil block glaucoma, 04eyes with angle closure glaucoma and 03 eyes had associated open angle glaucoma. Nine eyes had controlled IOP after lensectomy but 05 eyes needed trabeculectomy with MMC as a secondary procedure.

Preoperatively 54 eyes selected for lensectomy were classified in 2 groups. Group-I included 32 eyes (60%) and group-II had 22 eyes (40%) (Table 4). Postoperatively there was a significant improvement in BCVA, as shown in (Table 5).

Table 1: Age of patients presented with ectopia lentis (No = 50)

Age in years	No. of Patients n (%)
< 05	05 (10)
5-10	25 (50)
11-15	16 (32)
15-16	04 (8)

Table 2: Age of patients undergone lensectomy (54 eyes of 34 patients)

Age in years	No. of Patients n (%)
0 - 5	06 (11)
5 - 10	31 (57)
11 - 15	12 (22)

15 - 16	05 (10)
---------	---------

Table 3: Etiology of ectopia lentis in 50 patients

Etiology of Ectopia Lentis	No of Patients n (%)
Sporadic	24 (48)
Familial ectopia lentis	12 (24)
Marfan syndrome	11 (22)
Weil Marchesani syndrome	02 (04)
Suspected Homocysteinuria	01 (02)

Table 4: Pre operative visual acuity in 54 eyes

Visual Acuity	No. of Patients n (%)
HM - 6/60	32 (59)
6/48 - 6/30	22 (41)

Table 5: Post-operative best corrected visual acuity in 54 eyes

Visual Acuity	No. of Patients n (%)
HM - 6/60	11 (20)
6/48 - 6/24	05 (09)
6/18 - 6/15	29 (54)
6/12 - 6/7.5	09 (17)

Eleven eyes (20%) showed no significant improvement due to presence of poor prognostic factors. Causes of postoperative poor vision (HM to 6/60) in 11 eyes were presence of preoperative corneal opacity in 01 eye (9%), irreversible amblyopia in 03 eyes (27%), preoperative glaucomatous optic nerve damage in 06 eyes (55%), while 1 eye had postoperative retinal detachment.

Surgical complications occurred in 04 out of 54 operated eyes. Peroperatively posterior drop of lens fragments in one eye managed successfully by 3 port pars plana vitrectomy, retinal detachment within three weeks post operatively in 01 eye. Choroidal detachment occurred in both eyes of a patient who had Weil Marchasani syndrome and combined surgery (lensectomy and trabeculectomy with MMC) was

performed for ectopia lentis and glaucoma, but settled completely with conservative treatment in both eyes.

DISCUSSION

Ectopia lentis is perhaps the most common congenital lenticular anomaly other than cataract¹. Usually bilateral, this condition may be caused by extensive malformation of zonular ligaments. Ectopia lentis can occur as an isolated condition, as an association with other ocular disorders; or as a part of a systemic mesodermal disease, as in Marfan syndrome or Weil Marchesani syndrome. It can also occur as a complication of general metabolic disorders, such as homocystinuria, hyperlysenimia and combined xanthine and sulfite oxidase deficiency. It has also been reported with Ehler-Danlos syndrome, Sturge Weber syndrome⁵ and Stickler syndrome⁶. Of the systemic disorders associated with ectopia lentis, Marfan's syndrome, Weil Marchesani syndrome and homocystinuria account for over 75% of the observed lens displacement⁷. In this study, sporadic cases were 24 (48%), familial ectopia lentis in 12 patients (24%) and ectopia lentis in systemic disorders was seen in 14 patients (28%). Of these, systemic disorders associated with ectopia lentis, Marfan syndrome (Figure 1) in 11 patients (22%), Weil Marchesani syndrome in 2 patients (4%) and Homocystinuria in 1 patient (2%). Surgery was performed on 54 eyes and the BCVA 6/30 or less was found to be the commonest mode of presentation in 29 eyes (54%). This was followed by cataractous subluxated lens 11 eyes (20%) as shown in Figure 2, pupil block glaucoma 7 eyes (13%), clear subluxated lens bisecting the pupil 4 eyes (7.5%) as shown in Figure 3 and anterior dislocation 3 eyes (5.5%) as shown in Figure 4.

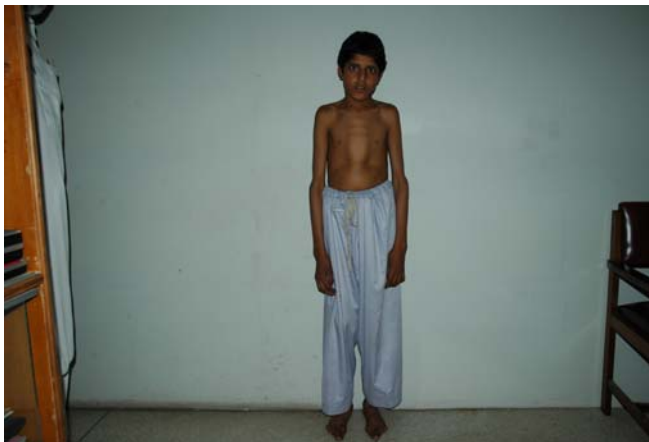

Fig. 1: Marfan Syndrome

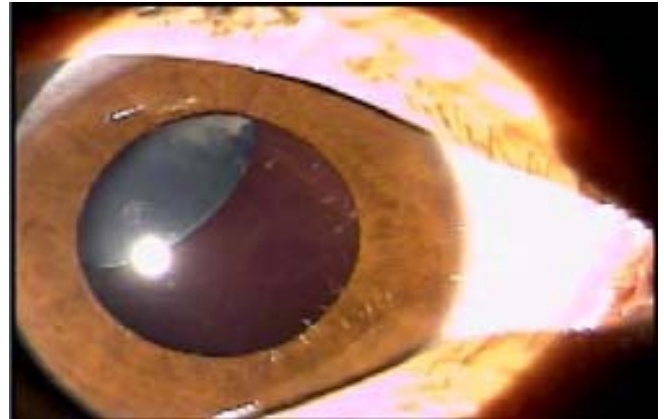


Fig. 2: Cataractous subluxated lens

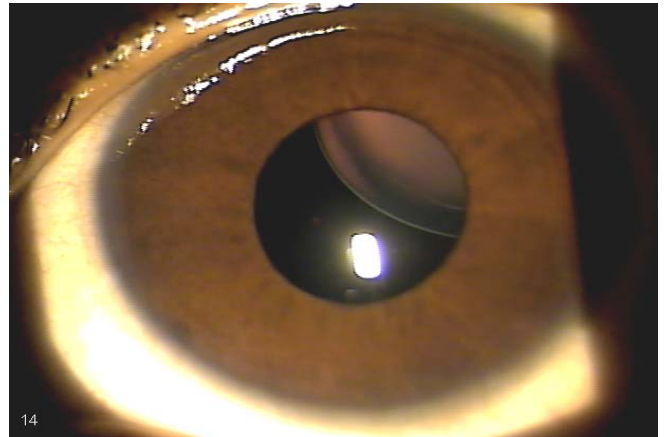


Fig. 3: Clear subluxated lens bisecting the pupil

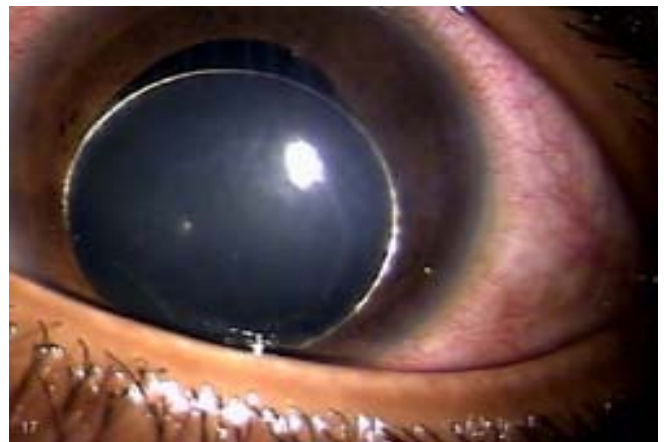

Fig. 4: Anterior dislocation of lens

Surgical treatment of ectopia lentis has traditionally been associated with poor visual outcome and a high complication rate in the past⁸. Numerous

techniques were used in the past but most of presented results were not encouraging⁸. Intracapsular or extracapsular extraction, used in the times when automated vitrectomy was not available, often caused uncontrolled vitreous loss and retinal detachment⁹. Cross and Jensen¹⁰ reported an improvement in visual acuity in 51%, vitreous loss rate in 30% and post operative detachment rate in 15% of 84 eyes of patients with Marfan's syndrome and homocystinuria who underwent lens removal using a variety of surgical techniques (aspiration, intracapsular removal and extracapsular removal). Subluxated lenses can be removed with closed eye lensectomy using vitrectomy instruments from either the anterior segment through the limbal incision or through the pars plana⁴. Modern microsurgical techniques yield very good results following either limbal or pars plana approach lensectomy for ectopia lentis^{11,12}. Retinal detachment, a frequent problem prior to lensectomy procedures using vitreous cutting instrument, is now a rare complication¹³. Contact lenses or spectacle correction of subsequent aphakia is effective and relatively straight forward. In one large study by Halpert and BenEzra¹³, the best corrected visual acuity of approximately 90% of eyes with ectopia lentis was found to have improved by 2 Snellen's lines or more following lensectomy.

In 1979, Peyman and associates¹⁴ reported on the first series of patients with ectopia lentis managed with pars plana lensectomy demonstrating good results and fewer complications. Similar results are also reported by Behki R, Neol and Clarke¹⁵. Reese and Weingeist¹² performed the removal of dislocated lens through a pars plana approach, obtaining satisfactory outcome in all 12 operated eyes. Plager and associates¹⁶ also reported similar encouraging results where over 90% achieved a visual acuity of 20/40 or better.

Both approaches are effective, and the selection depends on the comfort of the surgeon and familiarity with the technique.³ In our study we used within the bag lensectomy technique via limbal approach on 54 eyes. The main aspect of within the bag lensectomy is total aspiration of nucleus and cortical material within the capsular bag until the whole bag is emptied to prevent the posterior drop of lens fragments. A closed system endosurgical technique allows the anterior chamber to remain maintained, preserves normal anatomical relationships and prevents scleral and vitreous collapse¹⁷. Postoperative aphakic spectacles and contact lenses showed significant improvement in visual acuity. In our series, the postoperative BCVA

showed improvement in 43 (80%) out of 54 eyes. BCVA 6/18 and better was achieved in 38 eyes (71%).

Behki, Neol and Clarke¹⁵ treated a series of nine children (15 eyes) with limbal lensectomy. Improvement in postoperative BCVA was documented in all operated eyes ranging from 20/20 to 20/50. Shortt and associates¹⁸ reported the results of pars plana lensectomy for ectopia lentis in 24 eyes of 13 patients. Post operatively visual acuity was 6/9 or better in 17 of 22 eyes and 6/12 or better in 19 of 22 eyes.

Anteby, Isaac and BenEzra¹⁹ performed lensectomy via limbus and pars plana approach for ectopia lentis on 38 eyes and achieved a visual acuity (VA) 20/60 or better in 35 of 38 eyes 92.1%. Another study by Halpert and BenEzra¹³ reported improvement of VA of 20/40 or better in 54 of 59 (92%) operated eyes. They concluded that good and stable visual outcome can be obtained using within the bag lensectomy technique either through pars plana or limbal approach.

Alternative methods to glasses or contact lenses for correction of aphakia are available but their application for children still remains to be tested¹⁹. High IOP, corneal decompensation or both have developed in 80% of the children after follow up of 10 years with anterior chamber IOLs²⁰.

Scleral fixation of IOL could be another option instead of A/C IOLs in children. However frequent complications are encountered with this technique²⁰. Buckley in 1999,²¹ reported on the use of scleral sutured IOLs in children and concluded that this procedure had increased rate of complications. BenEzra²⁰ reported complications of scleral sutured IOLs in children, suture erosion and dislocation of IOL occurred 3 years after implantation of IOL, necessitating IOL removal. In another case,²⁰ an intractable chronic inflammation developed 18 months after surgery and alleviated only after removal of scleral fixated IOL. Sclerally fixated and in the bag fixation has been described in small series of children aged 8 to 11 years with Marfan's syndrome.²² Short term follow-up suggested improved post operative visual acuities; however anterior dislocation of IOL into A/C was reported.

Most paediatric ophthalmologists currently feel that, given the abnormal zonules in children with ectopia lentis and the limited capsular support for an IOL, the post operative refractive correction of the children undergoing lens surgery should remain

contact lenses or spectacles²³. Visual improvement occurs in nearly all cases but may be delayed reflecting long established ametropic amblyopia²⁴. Hing and coworkers²⁵ in their study, concluded that a child should have the lens removed and should wear aphakic correction as soon as the level of vision is inadequate for normal life or the situation of the lens is such as to make amblyopia likely.

Pfeifer and Mikek⁸ described a surgical technique based on the use of Cionni endocapsular tension ring, dry irrigation aspiration of lens material, centration of the capsular bag and foldable IOL implantation into the bag with no serious intraoperative or post-operative complications. The final BCVA improved in 9 out of 11 eyes. More studies on use of the modified capsular tension ring are required to provide pseudophakia as an ideal treatment of ectopia lentis in pediatric age group.

CONCLUSION

Within the bag lensectomy via limbal approach is a safe and effective technique for removal of subluxated lens in paediatric age group. This technique avoids major surgical complications. Post-operative aphakia corrected by spectacles or contact lenses is not ideal but is safer than other available alternatives like scleral fixation of IOL implant or anterior chamber IOL implant in children. In future IOL implantation with the help of modified capsular tension ring can be considered in paediatric age group to provide better optical correction.

ACKNOWLEDGEMENTS

I thank Professor Ziauddin Shaikh, Head of department Ophthalmology Civil Hospital Karachi, for his help and support in writing this paper. I also thank ORBIS International for their support in this study.

Author's affiliation

Dr. Sorath Noorani
Pediatric Ophthalmologist
PCB Cell, Eye OPD
Civil Hospital, Karachi

Dr. Ayesha Khan
Head of Pediatric Ophthalmology Department
Al Shifa Trust Eye Hospital, Rawalpindi

Dr. Shehla Rubab
Pediatric Ophthalmologist
Al Shifa Trust Eye Hospital, Rawalpindi

Dr. Khair Ahmed Choudhary
Trainee Pediatric Ophthalmology
Al Shifa Trust Eye Hospital, Rawalpindi

REFERENCE

1. **Eifring CW, Eifring DE:** Ectopia lentis: <http://www.emedicine.com/OPH/topic55.htm>.
2. **Marin S.** Inherited Eye Diseases: Diagnosis and Clinical Management. New York: MP Dekker, 1991:131-2.
3. **Tesser RA, Hess DB, Buckley EG:** Pediatric Cataracts and Lens Anomalies. In: Nelson L B, Olitsky S (ed). *Harley's Pediatric Ophthalmology*, 5 th ed. Pennsylvania: Lippincott Williams and Wilkins. 2005; 255-84.
4. **Wright KW.** Lens Abnormalities. In: Wright KW, (ed). *Pediatric Ophthalmology and Strabismus*, 2nd ed. New York: Springer. 2003; 450-80.
5. **Filato V, Guyer DR, Lustbuder JM, et al.** Dislocation of lens in a patient with Sturge - Weber syndrome. *Ann Ophthalmol.* 1992; 24: 260-2.
6. **Schlote T, Iker M, Knorr M, et al.** Coloboma and subluxation of lens in Stickler (Marshall) syndrome. *Klin Monatsbl Augenheilkd.* 1997; 210: 227-8.
7. **Cross HE.** Differential diagnosis and treatment of dislocated lenses. In: Bergsma D, Bron AJ, Cotlier E (eds). *The eye and inborn error of metabolism*. New York, Alan R. Liss, 1976: 335-46.
8. **Pfeifer V, Mikek K.** Ectopic Lens extraction in children. *Zdraw vestn* 2002; 71: 11-4.
9. **Merriam JC, Zheng L.** Iris hooks for Phacoemulsification of the subluxated lens. *J cataract Refract Surg.* 1997; 23: 1295-7.
10. **Cross HE, Jensen AD.** Ocular manifestation in the Marfan's Syndrome and homocystinuria. *Am J Ophthalmol.* 1973; 75: 405-20.
11. **Salehpour O, LavyT, Leonard J.** The surgical management of non-traumatic lenses. *J Pediatr Ophthalmol Strabismus.* 1996; 33: 8-13.
12. **Reese PD, Weingeist TA.** Pars plana management of ectopia lentis in children. *Arch Ophthalmol* 1987; 105:1202-4.
13. **Halpert M, Ben Ezra D.** Surgery of the hereditary subluxated lenses in children. *Ophthalmology* 1996; 103: 681-6.
14. **Peyman GA, Raichand M, Goldberg MF, et al.** Management of Subluxated and dislocated Lenses with Vitrochase. *Br J Ophthalmol.* 1979; 63: 771-8.
15. **Behki R, Neol LP, Clarke WN.** Limbal Lensectomy in management of ectopia lentis in children. *Arch Ophthalmol.* 1990; 108: 809-11.
16. **Plager DA, Parks MM, Halveston EM, et al.** Surgical treatment of Subluxated Lenses in children. *Ophthalmology* 1992; 99: 1018-21.
17. **Steven B, Koeing MD; William F et al.** Management of ectopia lentis in a family with Marfan's Syndrome. *Arch Ophthalmol.* 1996; 114: 1058-61.
18. **Shortt AJ, Lanigan B, O'Keefe M.** Pars plana Lensectomy for the management of ectopia lentis in children. *J Pediatr Ophthalmol Strabismus.* 2004; 41: 289-94.
19. **Anteby I, Isaac M, BenEzra D.** Hereditary Subluxated lenses: Visual performances and long-term follow-up after surgery. *Ophthalmology.* 2003; 110: 1344-8.
20. **BenEzra D.** IOLs for unilateral pediatric aphakia: early lenses and long-term follow-up. *Eur J Implant Refractive Surg.* 1990; 2: 285-7.
21. **Buckley EG.** Scleral fixated (sutured) posterior chamber IOL implantation in children. *JAA POS* 1999; 3: 289-94.



22. **Vadala P, Capozzi P, Fortunato M, et al.** Intraocular lens implantation in Marfan's Syndrome. *J Pediatr Ophthalmol and Strabismus*. 2000; 37: 206-8.
23. **Ian C. Lloyd.** The Lens. In: David Taylor, (ed). *Pediatric Ophthalmology and Strabismus*, 5th ed. London: Elsevier 2005; 432-40.
24. **Speedwell L, Russell- Eggitt I.** Improvement in visual acuity in children with ectopia lentis. *J. Pediatr. Ophthalmol Strabismus*. 1995; 32: 94-7.
25. **Hing S, Speedwell L, Taylor D.** Lens surgery in infancy and childhood. *Br J Ophthalmol*. 1990; 74: 73-7.