

Case Report

Loss of Vision after Laser Peripheral Iridotomy: A Case Report

P S Mahar¹, Asma Rahman², Abdul Sami Memon³
¹⁻³Department of Ophthalmology, Aga Khan University Hospital, Karachi

ABSTRACT

Laser Peripheral Iridotomy (LPI) is a common laser procedure carried out in patients with narrow or occluded irido-corneal angles at risk of developing angle closure glaucoma. Nd-YAG and Argon laser are used sequentially in our local population to create an iridotomy. Posterior segment complications are rare after this procedure and generally can occur due to direct laser induced damage. We report a 44-year old patient, who had LPI performed on his both eyes. Post laser patient complained of reduced vision in his left eye and was evaluated in our glaucoma clinic. On examination, his vision was 20/25 unaided in his right eye and 20/60 in his left eye with no further improvement. Optical coherence tomography (OCT) revealed presence of cystoid macular edema (CME) in his left eye responsible for his reduced vision.

Key Words: Laser Peripheral Iridotomy, Cystoid Macular Edema, Argon Laser.

How to Cite this Article: Mahar PS, Rahman A, Memon AS. Loss of Vision after Laser Peripheral Iridotomy: A Case Report. Pak J Ophthalmol. 2021, **37 (4)**: 431-435.

Doi: 10.36351/pjo.v37i4.1268

INTRODUCTION

Laser Peripheral Iridotomy (LPI) is the procedure of choice in patients with Primary Angle Closure Glaucoma (PACG), Primary Angle Closure (PAC) and Primary Angle Closure Suspects (PACS).¹ The procedure is also carried out in eyes with secondary causes of iridocorneal angle closure.²

LPI creates an alternative route for aqueous escape from posterior to anterior chamber thus relieving the relative pupillary block.³ In light colored eyes, Nd-YAG, can work fine but in brown Asian eyes due to heavily pigmented iris, combined Argon and YAG Iridotomy remains the treatment of choice.⁴

Although the procedure is commonly practiced in glaucoma clinics universally, it is not free of side effects and complications. Several possible post-laser complications have been reported following this procedure including transient rise in intraocular pressure, posterior synechiae formation, transient blurred vision, choroidal effusion, formation of focal lens opacities, corneal decompensation, aqueous misdirection, retinal hemorrhages and choroidal and retinal detachment.⁵

We report here a case of patient who developed blurred vision in his left eye after getting LPI in his both eyes simultaneously.

CASE REPORT

A 44-year-old male attended our glaucoma clinic with complaint of blurred vision in his left eye for last 2 weeks. He had been diagnosed with glaucoma and was using fixed combination of Timolol 0.5% and Dorzolamide 2% twice a day in his both eyes. His

Correspondence: P S Mahar
Department of Ophthalmology
Aga Khan University Hospital, Karachi
Email: salim.mahar@aku.edu

Received: May 07, 2021
Accepted: September 23, 2021

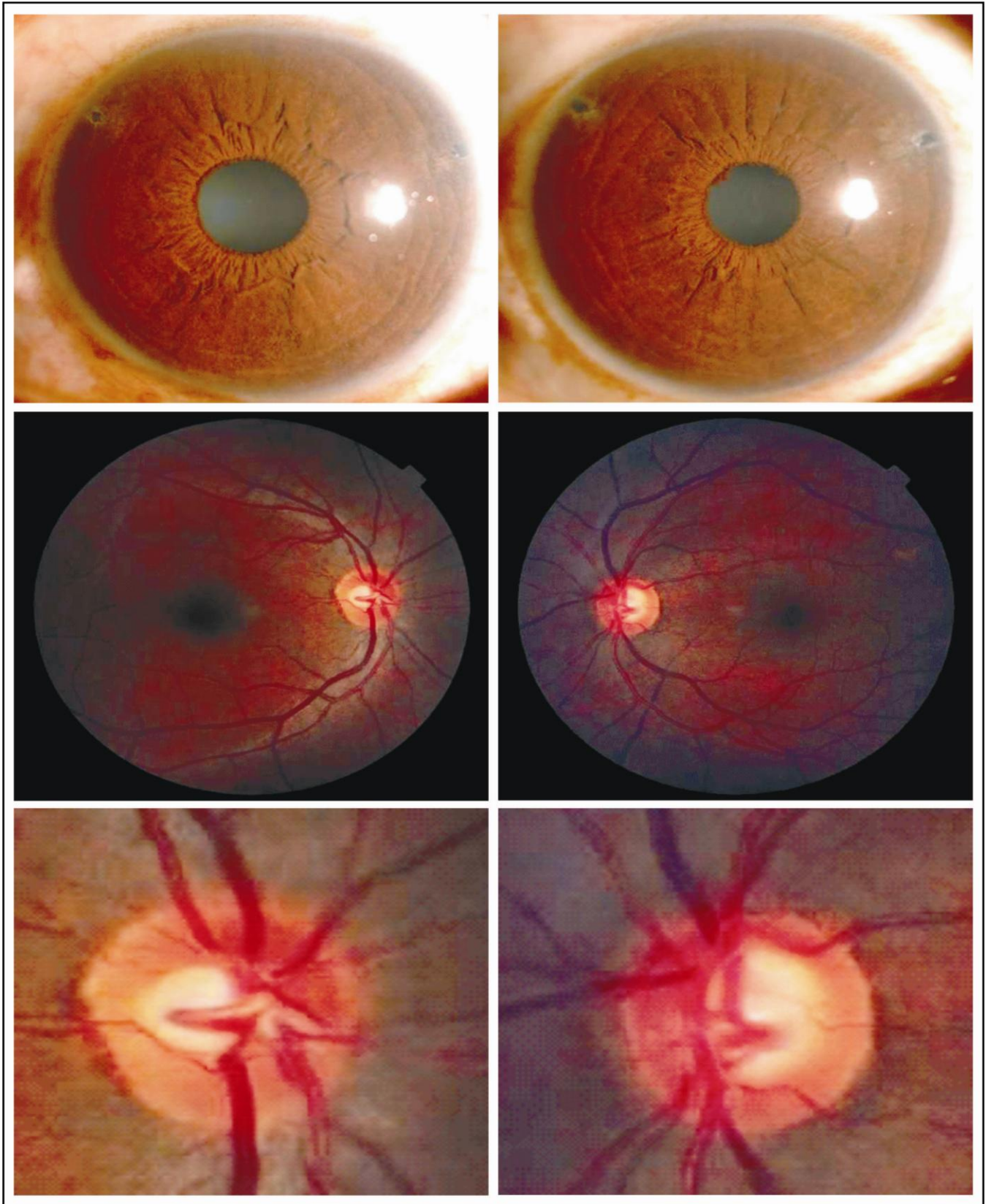


Figure 1: Above: Anterior Segment of Right and Left Eye showing Iridotomies; Middle: Fundus photographs of right and left eyes; Below: Optic discs of both eyes.

OCT RNFL Left Eye

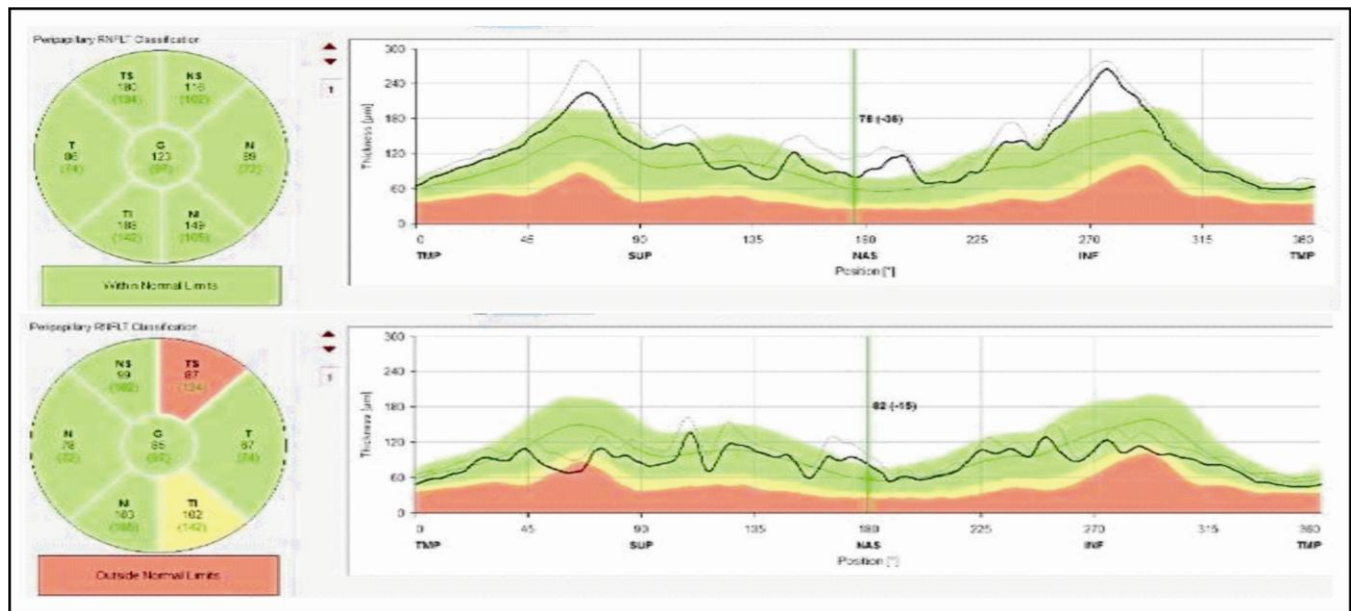


Figure 2: Optical Coherence Tomography of Right and Left Eye showing Retinal Nerve Fiber Layer Analysis (RNFL). Right RNFL appears normal while there is thinning of RNFL in supero-temporal quadrant in left eye.

treating physician advised him for LPI which was carried out simultaneously on his both eyes under topical anesthesia. The details of the procedure were not known. After the laser, he complained of blurred vision in his left eye. He did not have family history of glaucoma and no significant past and present medical or surgical history.

On examination in our clinic, his best corrected visual acuity (BCVA) was 20/25 unaided in the right eye and 20/60 in the left eye with no further improvement. His intraocular pressures with Goldmann Applanation Tonometer (GAT) were 16 mm Hg in his right and left eye. His corneas were clear and pupils round and reacting. His central corneal thickness (CCT) was 525 microns in his right eye and 530 microns in his left eye. Gonioscopy revealed Iridocorneal angles grade II in all quadrants by Shaffer’s classification. He had two iridotomies present at 10’O and 2’ O Clock position in both eyes and were patent (Figure 1). Media were clear and the dilated fundus examination with 90 DS Volk lens showed a cup disc ratio of about 0.3 with healthy rims in his right eye while it was calculated at 0.6 in the left eye (Figure 1). Left macular reflex appeared dull on further examination. Optical coherence tomography (OCT) of retinal nerve fiber layer (RNFL) and macula was requested. Right RNFL analysis was within

normal limits while left eye showed early thinning in superior-temporal area (Figure 2). Macular scans measuring 6.6 mm X 6.6 mm of right eye was normal while it showed presence of cystoid macular edema with central macular thickness (CMT) of 630 microns (Figure 3).

This patient was advised intravitreal injection of Bevacizumab (Avastin – Genintech, USA) in dose of 1.25 mg/0.05 ml in his left eye. This was carried out in the operating room under sterile condition. With patient’s history of glaucoma, he was given 2 tablets of Acetazolamide 250 mg, 6 hours before injection.

At 4 weeks postoperative, patient’s vision had recovered to 20/25 in his left eye unaided and a repeat OCT scan of macula showed flat retina (Figure 3).

DISCUSSION

Cystoid macular edema (CME) after LPI is one of the most uncommon complications of this procedure. Medline and PubMed search found only 2 reports of this complication. The first one reported in literature was in 1983 by Choplin.⁶ This has been followed by another report of delayed appearance of CME after LPI by Yang and colleagues published in 2018.⁷

Though Irvine – Gass syndrome remains the

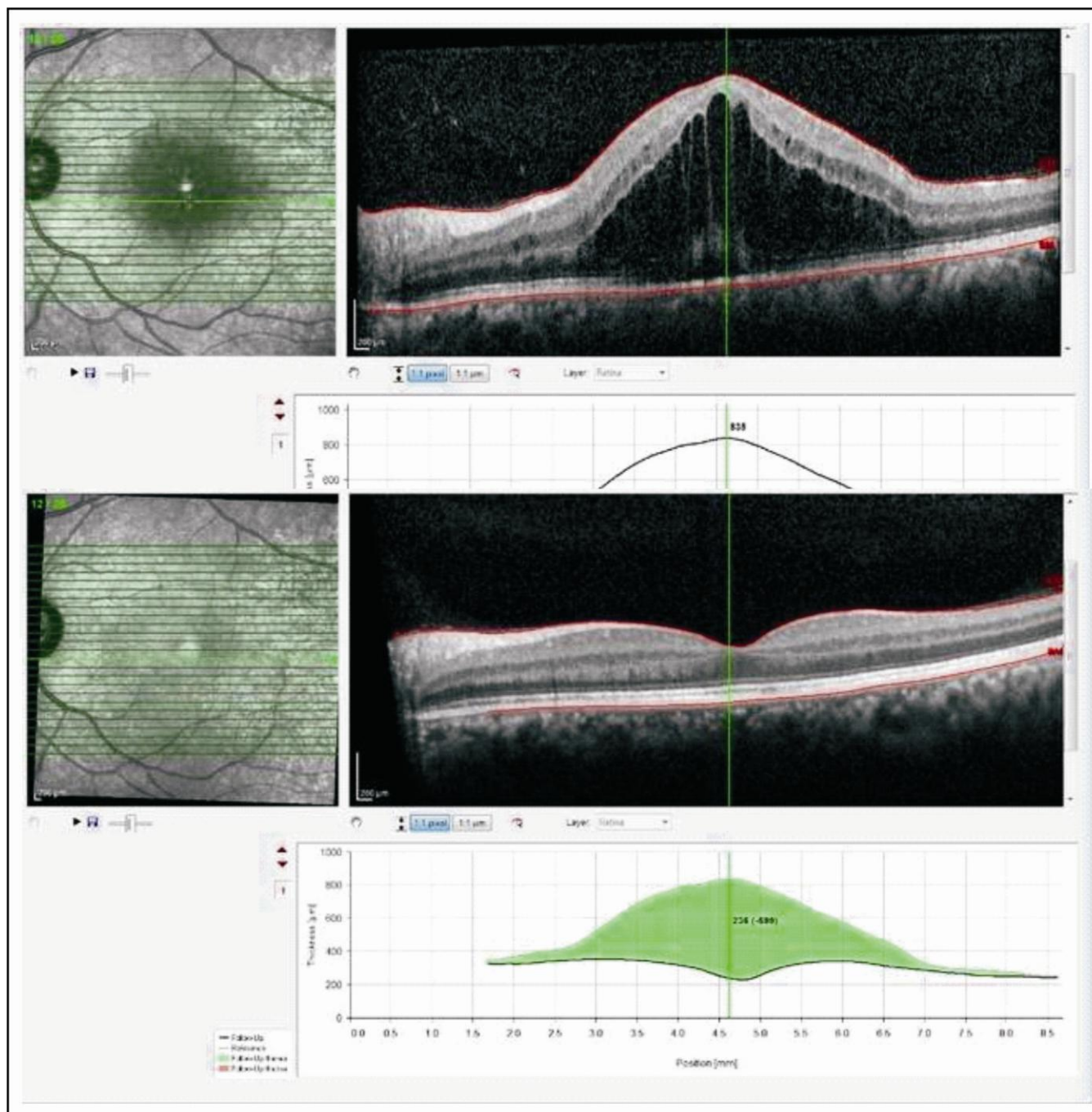


Figure 3: Optical Coherence Tomography of Left Macula showing presence Cystoid Macular Edema. Optical Coherence Tomography of Left Macula 1 month after intravitreal Bevacizumab.

common cause of CME after cataract surgery,⁸ there are numerous other conditions described with this clinical appearance of fluid filled cystoid spaces in macular area elegantly seen on the macular scan.

There are several mechanisms postulated for the development of the CME. The diffusion of inflammatory mediators such as prostaglandins can

cause increased permeability of retinal blood vessels resulting in outpouring of fluid.⁹ This theory is supported by the evidence that cyclooxygenase inhibitors such as non-steroidal anti-inflammatory drugs reduce the incidence of CME. We can theorize that laser application to the Iris can cause release of such mediators causing CME in our patient. As this

patient had LPI performed simultaneously on both eyes, this theory does not hold good. The patient developed CME only in one eye. The vitreo-macular traction (VMT) is another factor which can cause stress at the Muller cells and feet exerting traction force with release of basic fibroblastic growth factor (bFGF), vascular endothelial growth factor (VEGF) and platelet-derived growth factor (PDGF).¹⁰ This results in blood retinal barrier breakdown with development of edema. However, no sign of VMT was evident on patient's retinal examination. However, dispersion of normal vitreo-macular interface can occur due to the laser energy resulting in release of mediators leading to breakdown of blood retinal barrier with clinical appearance of CME. Vascular disorders such as diabetic retinopathy (DR) and Branch Retinal Vein Occlusion (BRVO) are one of main group condition, which can result in CME.¹¹ Our patient did not fall in any of these groups.

CONCLUSION

Cystoid macular edema in a patient after simultaneous laser peripheral iridotomy in both eyes is a rare entity. Multiple hypotheses can be formulated to explain it. However, to prove it further work has to be done.

REFERENCES

1. **Quigley HA.** Angle-closure glaucoma—simpler answers to complex mechanisms: LXVI Edward Jackson Memorial Lecture. *Am J Ophthalmol.* 2009; **148 (5):** 657-669.
2. **Prum BE Jr, Herndon LW Jr, Moroi SE, Mansberger SL, Stein JD, Lim MC, et al.** Primary Angle Closure Preferred Practice Pattern Guidelines. *Ophthalmol.* 2016; **123:** P1-P40.

3. **Lam DSC, Tham CCY, Congdon NG, Baig N.** Peripheral Iridotomy for Angle Closure Glaucoma. *Glaucoma Elsevier;* 2015: pp 708-715.
4. **Mirza AA, Nizamani NB, Khanzada MA, Talpur KI.** Efficacy and Complications of Modified Laser Iridotomy in Primary Angle Closure Glaucoma. *Pak Journal Ophthalmol.* 2016; **32 (4):** 195-200.
5. **Saha BC, Rashmi K, Sinha BP, Ambasta A, Kumar S.** Laser in Glaucoma: An Overview. *Int Ophthalmol* 2021; **41:** 1111-1128.
6. **Choplin NT, Bene CH.** Cystoid Macular Edema Following Laser Iridotomy. *Ann Ophthalmol.* 1983; **15 (2):** 172-173.
7. **Yang AY, Kempton J, Liu J.** Delayed Cystoid Macular Oedema after Uncomplicated Laser Peripheral Iridotomy. *Clin Exp Ophthalmol.* 2018; **46 (7):** 823-824.
8. **Benitah NR, Arroyo JG.** Pseudophakic Cystoid Macular Edema. *Int Ophthalmol Clin.* 2010; **50 (1):** 139-153.
9. **Shelsta HN, Jampol LM.** Pharmacologic Therapy of Pseudophakic Cystoid Macular Edema, 2010 Update. *Retina,* 2011; **31 (1):** 4-12.
10. **Bottos J, Elizalde J, Maia M.** Classifications of Vitreomacular Traction Syndrome: Diameter vs. Morphology. *Eye,* 2014; **28 (12):** 1107-1112.
11. **Spaide RF.** Retinal Vascular Cystoid Macular Edema: Review and New Theory. *Retina,* 2016; **36 (10):** 1823-1842.

Authors' Designation and Contribution

P S Mahar; Professor & Section Head: *Manuscript Writing and Final Review.*

Asma Rahman; Senior Medical Officer: *Collection of Data and Final Review.*

Abdul Sami Memon; Clinical Assistant Professor: *Data Analysis and Final Review.*

