

Neuroimaging in Neuro-Ophthalmology (Systematic Review)

Tayyaba Gul Malik¹, Khalid Farooq²

¹Department of Ophthalmology, Rashid Latif Medical College/Arif Memorial Teaching Hospital, Lahore

²Department of Radiology, Lahore Medical and Dental College/Ghurki Trust Teaching Hospital, Lahore

ABSTRACT

There are quite a number of neurological diseases, which initially present to the ophthalmologists. Based on the proper history and clinical findings ophthalmologists have to suggest the ancillary neuro-imaging to support their provisional diagnosis and reach the site of lesion. Unless the ophthalmologists are aware of the right imaging at right time and at right area to focus, there are many pitfalls. MRI and CT of the brain and orbit are important investigations in neuro-ophthalmology which if intelligently ordered can add to the diagnostic and management process. In general, MRI is the most commonly ordered investigation in neuro-ophthalmology with so many additional sequences as FLAIR, GRE, diffusion weighted imaging, spectroscopy, in addition to T1 and T2 weighted imaging. Having said that CT scan has its advantages in cases of bony pathologies and acute brain hemorrhages. This article reviews the indications and importance of different neuro-imaging techniques, based on the previous studies from 1997 to 2019.

Key Words: Neuro-ophthalmology, Magnetic Resonance imaging, Optic neuritis, Papilledema, Visual Pathway, Optic tract, Optic nerve, Meningioma, Glioma.

How to Cite this Article: Malik TG, Farooq K. Neuroimaging in Neuro-Ophthalmology (Systematic Review). Pak J Ophthalmol. 2020, **36 (2)**: 180-189.

Doi: 10.36351/pjo.v36i2.1026

INTRODUCTION

Neuro-imaging is an important part of neuro-ophthalmology but it cannot replace a thorough clinical examination. Rather ordering a relevant neuro-imaging test depends upon a detailed history and thorough evaluation in the clinics. Suggesting a right investigation at a right time can save time as well as money. It is very important for the ophthalmologists to have sufficient knowledge about which investigation is required in a particular case, when to use contrast, which views (coronal, axial, sagittal) are important in which case and which sequence is necessary. Keeping a radiologist fully informed about the positive clinical findings and the provisional diagnosis along with the

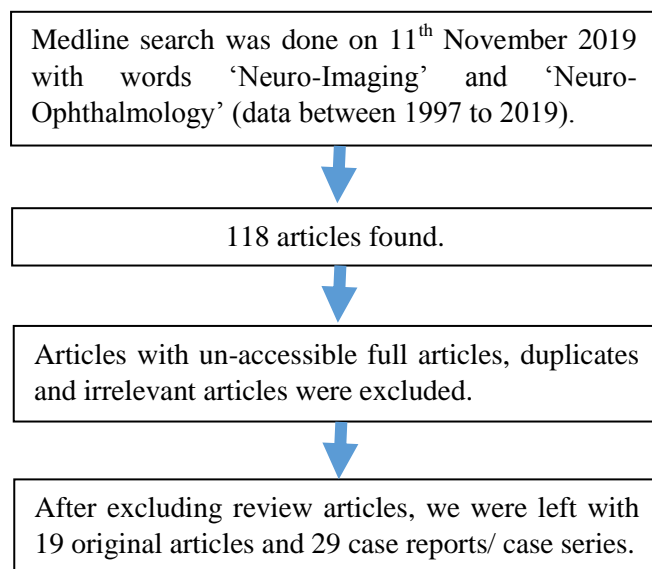
area of interest in neuro-imaging is also a mandatory part of neuro-imaging, failing which can lead to pitfalls in diagnosis. At times, the definite clinical findings are not supported by neuro-imaging, in which case it is important to have a detailed discussion of the case with the radiologist. Sometimes very thin slices of a particular area of interest are required and which are missed in general thick slice scans. At other times, some additional investigation is needed to prove a definite clinical diagnosis.

The purpose of this review article was to find out which neuro-imaging tests are commonly used in neuro-ophthalmology and what were the presenting complaints of the patients for which these investigations were suggested. Keeping in view the published data an exercise is done to make clear when to order which of the neuro-imaging test to save time and money by avoiding wrong investigation or right investigation in wrong time and area.

Correspondence to: Professor Tayyaba Gul Malik
Department of Ophthalmology, Rashid Latif Medical
College/Arif Memorial Teaching Hospital, Lahore

MATERIAL AND METHODS

PRISMA guidelines were followed for this systematic review. A literature search was conducted on the 11th November 2019. NCBI Pubmed database was used with search terms 'neuroimaging' and 'neuro-ophthalmology' (1997 to 2019). One hundred and eighteen results were found. Articles with un-accessible full articles, duplicates and irrelevant articles were excluded. We were left with 70 items. This produced a list of 19 review articles, 19 original articles and 29 case reports or case series. Review articles were not included in this review. Studies, which did not use neuro-imaging in diagnosis of neuro-ophthalmology cases, were excluded from our study. We also excluded articles, which were published only as abstracts or were presented only in conferences without publication. One of the study was also removed because it did not mention the type of imaging used in the study. The flow chart for data retrieval is shown below.



RESULTS

In 19 original articles, total number of patients were 1350 (858 females and 492 males), with age ranging from 1 year to 81 years. There were 14 retrospective studies, 2 case control studies, 2 cross sectional studies and 1 interventional study. There were 29 case reports/case series, which included 72 patients (45 females and 27 males) with age ranging from 3 months to 89 years.

Neuro-imaging was done for complaints of diplopia, decreased vision, visual field defects, swollen optic discs, headache, pulsatile tinnitus, nausea, vomiting associated with headache, ocular motor nerve palsies, Horner syndrome, nystagmus, presumed cortical blindness, supranuclear gaze palsy, ptosis and as part of investigation in cases of neurofibromatosis. The final diagnoses included idiopathic intracranial hypertension, meningioma, glioma of visual pathway, multiple sclerosis, trochlear headache, Pituitary adenoma, Craniopharyngioma, ischemic strokes, hemorrhages, aneurysms, herpes simplex encephalitis, Stenosis of dural sinuses and cerebral venous sinus thrombosis. Diagnoses of case reports and series included; Hair dresser syndrome, Pseudotumor Cerebri, Horner Syndrome, Tolosa-Hunt Syndrome, Sixth Nerve Palsy, Migraine, Amyloidosis, Encephalopathy Syndrome, Orbital Apex Syndrome, Behr Syndrome, Optic Nerve Hypoplasia, 4th Nerve Palsy, Pituitary Apoplexy, Eight and a half syndrome, Cholesterol Granuloma of the Sphenoidal sinus, Craniopharyngioma and Alzheimers Disease. Other neuro-imaging results included Arnold Chiari Malformation, Carotico-Cavernous Fistula, Vertebrobasilar ischemia, cerebral edema, non-Hodgkin's Lymphoma, ectopic posterior pituitary gland, Rathke's cleft cyst, carcinomatous meningitis secondary to metastatic breast cancer, neurosarcoidosis and Carotid artery dissection.

MRI scan was the most commonly ordered investigation followed by CT scan. Other ancillary sequences were done when initial MRI and CT were normal. The investigations, which were done in decreasing order of frequency, were as follows:

1. MRI.
2. CT.
3. MRV.
4. CT Angiography.
5. MRA.
6. FLAIR.
7. PET.
8. DTI and Diffusion Tensor Tractography.
9. Arteriography.

Table 1: Details of original articles (neuro-imaging in neuro-ophthalmology from 1997 to 2019).

Author	Study Design	Sample Size	Provisional Diagnosis	Neuroimaging	Findings
Gondi KT, et al, ¹³ 2019	Case control study	53	IIH (Idiopathic intracranial hypertension)	MRI, CT, MRV	Empty sella, globe flattening, prominent perioptic cerebrospinal fluid, venous sinus stenosis
Park KA, et al, ¹⁴ 2019	Retrospective	127	Ocular motor nerve palsies	MRI	Inflammatory lesions and neoplasms
Koytak PK, et al, ¹⁵ 2018	Retrospective	35	Optic nerve sheath meningioma	MRI	Diagnosis of Optic nerve sheath meningioma was confirmed
Bursztyn LLC, et al, ¹⁶ 2018	Retrospective	92	Optic Neuritis	MRI	83.7% positive results for on MRI
Khadse R et al, ¹⁷ 2017	Retrospective	40	Optic Neuritis	MRI	Isolated optic nerve enhancement, demyelinating foci in frontal lobe and parieto-occipital lobe
Kowal et al, ¹⁸ 2017	Retrospective	24	Optic tract lesions	MRI, FLAIR	Ischemic strokes, tumors, hemorrhages, vascular malformation, demyelination, encephalitis
Aguilar-Pérez M et al, ¹⁹ 2017	Retrospective	51	IIH	MRI, MRV	Empty sella, Stenotic dural sinuses
Chang RO, et al, ²⁰ 2016	Retrospective	12	IIH	MRI	Empty sella
Ming Ge, et al, ²¹ 2015	interventional	11	Optic pathway gliomas	Diffusion Tensor Tractography	Diagnosis of Optic nerve Glioma was confirmed
J. H. Smith, et al, ²² 2014	Retrospective	25	Trochlear headaches	MRI and CT	Normal imaging
Balk LJ, et al, ²³ 2014	case control study	222	MS	MRI, FLAIR, DTI	Integrity of the optic radiations (FA) was significantly impaired in patients with MS. Atrophy of the visual cortex, grey and white matter.
Kennedy de Blank PM, et al, ²⁴ 2013	Retrospective	50	Optic pathway gliomas	MRI /DTI	Optic nerve axons and myelin sheath integrity was disturbed
Mehta et al, ²⁵ 2012	Retrospective	157	Optic neuropathy and cranial nerve palsies.	CT, CTA, MRI, MRA, MRV	28.9% of neuroimaging tests requested by neuro-ophthalmologists resulted in an abnormal finding
S. Ambika, et al, ²⁶ 2010	Retrospective	50	IIH	CT, MRI, MRV	25 normal, others had empty sella and stenotic dural sinus
Agarwal P, et al, ²⁷ 2010	Retrospective	308	IIH	MRI, MRV	35 patients had cerebral venous sinus thrombosis
Wolfe S, et al, ²⁸ 2008	Cross sectional	125	Miscellaneous conditions	MRI, CT	.18% Positive imaging
Lee AG, et al, ²⁹ 2005	Retrospective	91	Optic tract lesions	MRI, CT	93 normal, lesions found in 18 cases
Mcfadzean R, et al, ³⁰ 1998	Cross sectional	100	Isolated 3rd nerve palsy	CTA	72 were normal, aneurysm in 18 and 10 had other abnormalities
Jacobson DM, ³¹ 1997	Retrospective	71	Parieto occipital lobe lesions	MRI	Parieto occipital lobe lesions confirmed

Table 2: Details of case reports/case series (neuro-imaging in neuro-ophthalmology; 1997 to2019).

Authors	No. of Cases	Diagnosis	Neuroimaging	Findings
Jonathan A, et al, ³² 2019	3	Hair dresser syndrome	CT/CTA or MRI/MRA)	Vertebrobasilar ischemia
Tommy L.H. et al, ³³ 2018	3	IIH	MRI, MRV	Bilateral Dural Venous Sinus Stenosis
Karti DT, et al, ⁴ 2018	1	Horner syndrome	CT, MRI (cervical)	Multiple spinal root cysts between C7 and T1 segments
Ravindran K, et al, ³⁵ 2017	1	Tolosa–Hunt Syndrome	MRI/Cerebral Angiogram	Inflammatory stranding of the right orbital apex and extension into the lateral wall of the right cavernous sinus

Authors	No. of Cases	Diagnosis	Neuroimaging	Findings
Brandon J, et al, ³⁶ 2017	1	Sixth Nerve Palsy	MRI and MRA	Normal
Nadha A, et al, ³⁷ 2017	1	Migraine	MRI, CT	Normal
Oana M, et al, ³⁸ 2017	1	Amyloidosis	CTA/MRA/ MRI	Multifocal patchy and confluent vasogenic edema in the cerebral hemispheres, hemosiderin deposition from microhemorrhages
Chou MC, et al, ³⁹ 2017	1	Encephalopathy Syndrome	MRI/MRA/CT/ FLAIR	Hyperintense signal change at periventricular, parieto-occipital, cerebellar, and brainstem areas visualised in FLAIR
Carlen A, et al, ⁴⁰ 2017	1	Orbital Apex syndrome	CT	Retro-orbital mass. Excision biopsy showed non-Hodgkin's lymphoma
Hidehiro Oku, et al, ⁴¹ 2016	1	Sixth Nerve Palsy	MRI and MRA	Aneurysm of intracavernous carotid artery
Raof N, et al, ⁴² 2015	1	Sixth Nerve Palsy	MRI and CT	Skull base Endochondroma
Kleffner I, et al, ⁴³ 2015	2	Behr syndrome	MRI	Bilateral hypointense signals in the globus pallidus, the putamen, and the substantia nigra as well as a cerebellar atrophy
Vaphiades MS, et al, ⁴⁴ 2015	1	Progressive Supranuclear Palsy-Like Syndrome	MRI/MRI tractography/ (fMRI),	normal
Koukkoulli A, et al, ⁴⁵ 2015	1	Ophthalmoplegia with lid SCC	MRI	Perineural Spread of Cutaneous Squamous Cell Carcinoma
Cheng HC, et al, ⁴⁶ 2015	5	Optic nerve hypoplasia	MRI	Ectopic posterior pituitary gland, agenesis of septum pellucidum, Rathke's cleft cyst
Madgula, et al, ⁴⁷ 2014	1	4th nerve palsy	MRI	Metastatic breast cancer
Berkenstock M, et al, ⁴⁸ 2014	1	Pituitary Apoplexy	MRI and MRA	Pituitary adenoma with haemorrhage
Bansal S, et al, ⁴⁹ 2014	1	Third nerve palsy	MRI	Neurosarcoidosis
Rosini F, et al, ⁵⁰ 2013	1	8 ½ Syndrome with Hemiparesis and Hemihyesthesia: The Nine Syndrome?	MRI	Ischemia of right pons involving the abducens nucleus, adjacent medial longitudinal fasciculus(MLF), and facial colliculus, extending to the ipsilateral mediallemniscus and corticospinal tract
Peher N, et al, ⁵¹ 2011	1	Cholesterol Granuloma of the sphenoidal Sinus	MRI	A homogenous T1 and T2 hyperintense lesion causing expansion of sphenoidal sinus
Reyes KB, et al, ⁵² 2011	1	Craniopharyngioma	MRI	Suprasellar cystic lesion compressing the chiasm, flattening the pituitary gland
Raghavendra S, et al, ⁵³ 2010	1	4th nerve palsy	MRI	Mid brain hemorrhage
Sánchez VM, et al, ⁵⁴ 2006	1	Alzheimer's Disease	PET scan	Parietal-occipital bilateral hypo-metabolism
Andrew GL, et al, ⁵⁵ 2004	8	Alzheimer's Disease	MRI AND PET	Hypoperfusion in the parieto-occipital areas.MRI showed pariet-occipital atrophy
Freedman KA, et al, ⁵⁶ 2004	1	Nonketotic Hyperglycemic patient	MRI	Normal
Madhura A. et al, ⁵⁷ 2004	2	third nerve palsy	MRI and MRA	Internal carotid artery aneurysm and arteriovenous fistula arising
Parsa CF, et al, ⁵⁸ 2001	13	Optic nerve gliomas	CT and MRI	Gliomas of optic nerve and chiasma
Andrew GL, et al, ⁵⁹ 2000	8	Acute optic neuropathy	MRI	3 sarcoidosis, 4 meningioma, metastasis
Mark L, et al, ⁶⁰ 1998	9	Miscellaneous	MRI, CT, Arteriography	Carotid artery dissection, pituitary tumour, ischemic occipital lobe injury, Arnold Chiari Malformation, CCF, Carotid stenosis, MS, optic nerve sheath meningioma

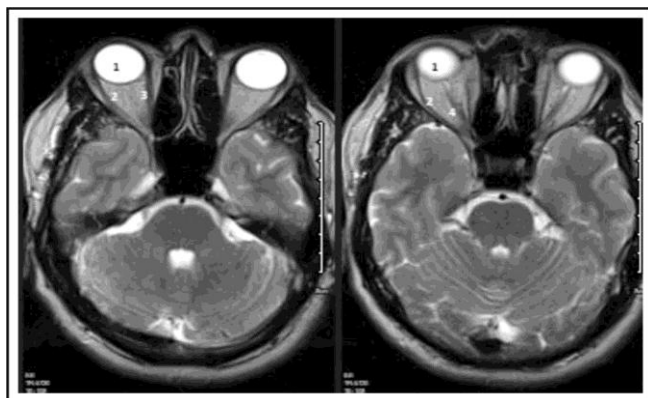


Fig. 1: Axial T2 images; 1) Eyeball, 2) Lateral Rectus, 3) Medial Rectus 4) Optic Nerve.

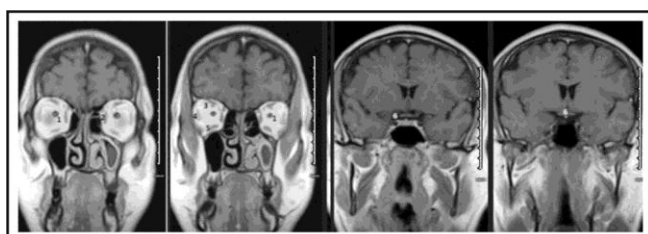


Fig. 2: Coronal T1 images through orbit; 1) Optic nerve 2) Medial Rectus 3) Superior Rectus 4) Lateral Rectus 5) Inferior Rectus 6) Optic chiasm.

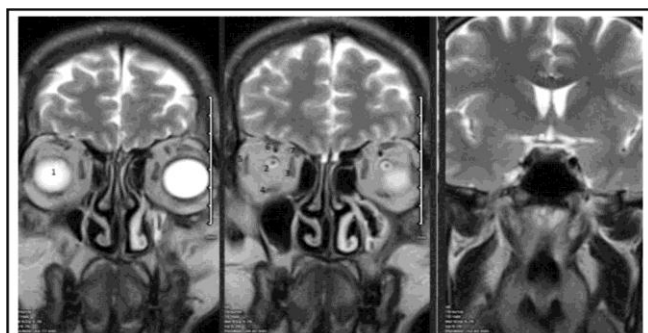


Fig. 3: Coronal T2 images; 1) Eyeball, 2) Optic nerve, 3) Medial Rectus, 4) Inferior Rectus, 5) Lateral Rectus, 6) Superior Rectus 7) Superior Oblique 8) Optic chiasm.

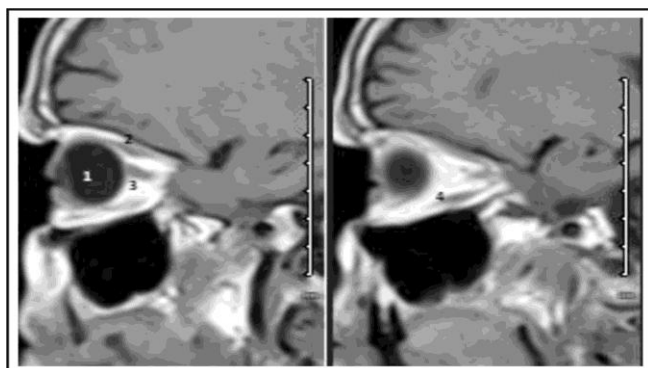


Fig. 4: Sagittal T1 images; 1) Eyeball, 2) Superior Rectus, 3) Optic Nerve, 4) Inferior Rectus.

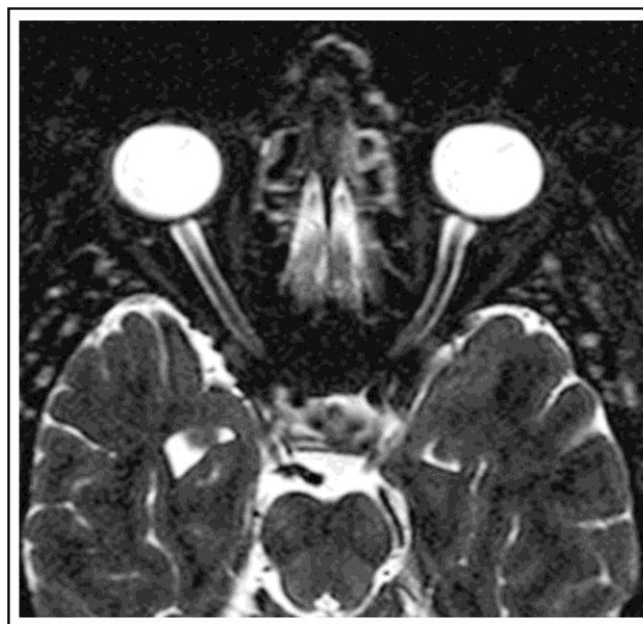


Fig. 5: Gadolinium contrast with fat suppression showing enhancement of optic nerve sheath.

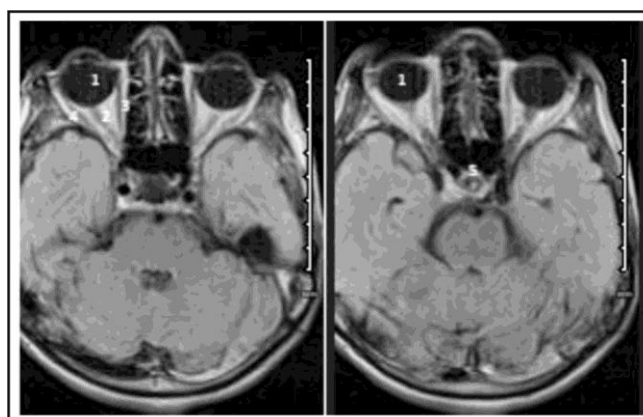


Fig. 6: Axial Flair images; 1) Eyeball, 2) Optic nerve, 3) Medial Rectus 4) Lateral Rectus, 5) Optic Chiasma.

DISCUSSION

In this systematic review only NCBI Pubmed database was used with search terms neuroimaging AND neuro-ophthalmology (1997 to 2019). The details of the studies and case reports are depicted in table 1 and 2. When we searched Pakistan Journal of Ophthalmology website from 2006 to 2019, only 14 articles were found related to neuro-ophthalmology. After excluding the articles, which did not include neuro-imaging, we were left with 5 case reports and 5 original articles. Case reports included CSF rhinorrhea¹, Ewing Sarcoma², Optic disc drusen³, traumatic optic neuropathy⁴ and tuberous sclerosis⁵. Original articles

included headache⁶, head trauma⁷, meningiomas of visual pathway⁸, Retinoblastoma⁹ and systemic associations of optic nerve diseases¹⁰.

In the following paragraphs, the commonly used neuro-imaging techniques and important sequences are discussed based on the articles reviewed through Pubmed search.

Magnetic Resonance Imaging (MRI)

The basic mechanism of MRI is the rearrangement of charged hydrogen ions after exposure of a tissue to a short electromagnetic pulse. Relaxation times of the tissues depend upon their characteristics and a tissue may be T1 weighted or T2 weighted. The magnetic field in MRI is expressed in Tesla (T). The commonly used field is 1.5T to 3.0T¹¹.

In T1 weighted images, CSF and vitreous appear dark and it is good for studying normal anatomy. In T2 weighted images, water appears hyperintense. Hence, the edematous tissues will be differentiated from the surrounding tissues as hyperintense. Optic nerve gliomas can be seen as tubular or fusiform enlargement of the nerve, which appear isointense to hypointense when compared with the adjacent tissues on T1-weighted MRI and enhance after gadolinium injection¹². Optic nerve meningiomas appear separate from the optic nerve on coronal views. It is visible in the form of a concentric ring around the nerve.

In patients with Idiopathic Intracranial Hypertension (IIH), T1-weighted images of the brain may show an empty sella turcica while axial T2-weighted MRI images of the orbit show distension and tortuosity of the optic nerve sheaths. Flattening of the posterior globe is also an MRI sign of IIH¹². Afferent and efferent visual pathways are also best detected by MRI studies (Figures 1, 2, 3, 4).

However, in the presence of acute hemorrhage and bony abnormalities, CT is a better option.

Gadolinium contrast studies is a special contrast medium, which shows up when placed in a magnetic field. When given through intravenous route, it remains inside the vessels unless there is a defect in the blood brain barrier. It is used with T1 weighted images. It helps in enhancing the brightness of tumour images and inflammatory lesions. Sellar masses are also best visualized with contrast enhanced T1 weighted images. Postcontrast T1-weighted images can be helpful in diagnosing Giant cell arteritis¹², in which case there is increased vessel wall thickness and

edema.

Fat-suppression techniques are used in various conditions including orbital pathologies. Orbital fat on conventional T1-weighted imaging makes it difficult to differentiate from other normal tissues (optic nerve and Extraocular muscles), tumors, inflammatory lesions and vascular malformations. There are two types of fat-suppression sequence used in neuro-ophthalmology.

1. T1 weighted images with gadolinium contrast and fat suppression allows the optic nerve sheath lesions to be enhanced¹².
2. STIR (short T1 inversion recovery) is used without contrast and is quite optimal sequence for diagnosing intrinsic lesions of the intraorbital optic nerve (e.g. optic neuritis).

Inflammation of the Optic nerve sheath is better detected by gadolinium-enhanced fat-saturated T1-weighted MRI, in which they appear as circumferential optic nerve sheath enhancement and on axial views these are seen as tram-track sign (Figure 5). Fat suppression techniques are also useful in confirming the fat-containing lesions, such as Dermoid cysts and lipomas. Thus for optic nerve sheath and optic nerve lesions, fat suppression is a gold standard.

Diffusion-Weighted Imaging

Diffusion-weighted imaging (DWI) is a special MRI technique that is based on the microscopic random Brownian motion of water. It is useful in detecting acute ischemic strokes. This technique is useful in very early stage of ischemic stroke when the changes are undetectable on T1 and T2 weighted MRI¹². As different stages of infarction can also be identified by DWI, this technique is helpful in distinguishing vasogenic reversible ischemia from irreversible ischemia in patients with cortical blindness and brainstem ischemia.

(FLAIR) Sequence

As CSF is bright on T2-weighted images, it becomes difficult to differentiate periventricular lesions from CSF signal. In fluid-attenuated inversion recovery, a T2-weighted image of CSF signal is suppressed to allow better detection of adjacent pathology. FLAIR sequences also help to highlight inflammatory changes¹² (Figure 6).

Gradient Recalled Echo (GRE) or susceptibility-weighted imaging (SWI) is helpful in diagnosing micro hemorrhages (within the first few hours) (Figure 2).

FIESTA and CISS (fast imaging employing steady-state acquisition and constructive interference in steady-state). The structures surrounded by CSF and isodense to CSF in T1 and T2 weighted images are better visualized by this technique. Orbital masses, which arise from the orbital nerves can be better detected with this technique.

Magnetic Resonance Venography (MRV) and Magnetic Resonance Arteriography (MRA)

MRA is a very good technique, which has reduced dependency on Conventional invasive angiography. MRA relies on blood flow within the vessels and hence contrast is not required. However, the thrombosed aneurysm and small aneurysms are missed. MRV is used to detect venous sinus thrombosis or venous stenosis¹¹.

Diffusion Tensor Imaging and Diffusion Tensor Tractography

DTI and DTT can be helpful in visualizing the axon and myelin integrity. Data from DTI is used to reconstruct a 3D images in DTT.

Magnetic Resonance Spectroscopy is capable of detecting brain metabolites and hence help in distinguishing between neoplasms, demyelinating lesions, radiation necrosis, inflammatory lesions and mitochondrial disorders that can affect the visual pathways.

Limitations of MRI include bony defects and acute haemorrhages, which are not detected on MRI. Magnetic foreign bodies, cardiac pace markers, ferromagnetic aneurysm clips are contraindications for MRI. The test is also not suitable for claustrophobic patients.

Computed Tomography (CT) uses X-rays to obtain images, which are then computed to form cross-sectional images. White is the maximum density of the tissue as in bones and black is the minimum density as in air. Iodinated contrast is used to improve the visualization of structures but allergy to iodine and renal failure are contraindications. Use of contrast in

acute hemorrhage, bony injury and in case of foreign bodies, can mask the visibility.

Optic nerve head drusen and tumours that show calcification e.g., Craniopharyngiomas, Meningiomas and Retinoblastomas can be detected with CT scan. Especially in cases of optic nerve sheath meningioma, CT shows perineural calcification in the form of “tram-tracking”. Hyperostosis of the neighboring bones is also a diagnostic sign¹².

In cases of traumatic optic neuropathy, CT scan can help in detecting the optic canal fracture, edema (or blood) within the optic canal (or optic nerve sheath), intraconal hematoma, or foreign body/fracture fragments causing impingement on the optic nerve.

Fludeoxy Glucose (FDG)-PET: Positron emission tomography (PET) is a sequence, which is used in diagnosing inflammatory and/or neoplastic processes. Fluorodeoxy glucose (FDG) is a metabolic marker. Greater uptake of glucose by the inflammatory and neoplastic lesions can be helpful in diagnosis. Large vessel vasculitis in GCA and extraocular muscle inflammation in Graves disease is detected by this technique¹².

Computed Tomographic Angiography and Venography (CTA, CTV): Extremely thin slices of brain are taken to investigate intracranial aneurysms. CTV is a good diagnostic technique for cerebral venous sinus thrombosis. Contrast is injected and the patient is exposed to radiations.

Conventional catheter angiography was once the only diagnostic test for intracranial aneurysm but now CTA and MRA have surpassed its use and it is only reserved for the patients in which the CTA and MRA are not diagnostic¹².

Limitation of this systematic review is the use of only one database (Pubmed). Other databases and gray literature/unpublished data were also not included.

CONCLUSION

Relevant history with detailed clinical examination along with the provisional diagnosis and the area of interest for neuro-imaging must be included in the investigation form. In case of any confusion, it is better to consult a radiologist, for the best interest of the patient, before filling the investigation form rather than writing a wrong investigation.

Authors' Designation and Contribution

Tayyaba Gul Malik; Professor: *Study design, literature search, data acquisition, data analysis, manuscript writing, final review.*

Khalid Farooq; Professor: *Study design, data acquisition, final review.*

REFERENCES

1. **Malik TG, Khalil M, Ain Q.** Chronic Rhinorrhea. Pak J Ophthalmol. 2016; **32 (4)**: 238-240.
2. **Abbasi S, Cheema A.** Ewing Sarcoma of Orbit with Intracranial Extension. Pak J Ophthalmol. 2015; **31 (2)**: 111-114.
3. **Memon GM, Zafar S, Shakir M, Kamil Z, Bokhari SA.** Bilateral Optic Disc Drusen in Hypermetropic Children of a Family. Pak J Ophthalmol 2012; **28 (3)**: 163-165.
4. **Awan AH.** Traumatic Optic Neuropathy. Pak J Ophthalmol. 2007; **23 (2)**: 100-102.
5. **Chaudary R, Riaz A.** Tuberos Sclerosis Complex. Pak J Ophthalmol. 2018; **34 (4)**: 295-297.
6. **Malik TG, Farooq K, Ayesha E.** Headache: Investigate or Not to Investigate? Pak J Ophthalmol. 2017; **33 (1)**: 26-29.
7. **Abbasi KZ, Qadeer B, Raza A.** Ocular Manifestations Associated with Head Injury. Pak J Ophthalmol. 2016; **32 (2)**: 111-116.
8. **Malik TG, Farooq K, Khalil M.** Clinical and Neuroimaging Patterns of Meningiomas of Visual Pathway. Pak J Ophthalmol. 2015; **31 (2)**: 101-104.
9. **Farrukh S, Saghir F, Zubair M, Amin M.** Optic Nerve Involvement in Retinoblastoma: Role of Computed Tomography with and without Contrast. Pak J Ophthalmol. 2009; **25 (4)**:
10. **Rehman M, Aftab AM, Khan SA, Ahmad I.** Optic Nerve Diseases and its Systemic Associations. Pak J Ophthalmol. 2017; **33 (3)**: 174-181.
11. **Hoch MJ, Bruno MT, Shepherd TM.** Advanced MRI of the optic nerve. J Neuroophthalmol. 2017; **37 (2)**: 187-196.
12. **Costello F, Scott JN.** Imaging in Neuroophthalmology. Continuum (Minneap Minn). 2019; **25 (5)**: 1438-1490.
13. **Gondi KT, Chen KS, Gratton SM.** Asymptomatic Versus Symptomatic Idiopathic Intracranial Hypertension in Children. Journal of Child Neurology, **20 (10)**: 1-6. DOI: 10.1177/0883073819858455.
14. **Park KA, Oh SY, Min JH, Kim BJ, Kim Y.** Cause of acquired onset of diplopia due to isolated third, fourth, and sixth cranial nerve palsies in patients aged 20 to 50 years in Korea: A high resolution magnetic resonance imaging study. Journal of the Neurological Sciences, 2019; **407**: 116546.
15. **Koytak PK, Bruce BB, Peragallo JH, Newman NJ, Biousse V.** Diagnostic Errors in Initial Misdiagnosis of Optic Nerve Sheath Meningiomas. JAMA Neurol. Doi:10.1001/jamaneurol.2018.3989
16. **Bursztyn LLCD, De Lott LB, Petrou M, Cornblath WT.** Sensitivity of orbital magnetic resonance imaging in acute demyelinating optic neuritis. Can J Ophthalmol. 2019; **54 (2)**: 242-246. Doi: 10.1016/j.jcjo.2018.05.013.
17. **Khadse R, Ravindran M, Pawar N, Maharajan P, Rengappa R.** Clinical profile and neuroimaging in pediatric optic neuritis in Indian population: A case series. Indian J Ophthalmol. 2017; **65**: 242-5.
18. **Kowal KM, Rodriguez FFR, Srinivasan A, Trobe JD.** Spectrum of Magnetic Resonance Imaging Features in Unilateral Optic Tract Dysfunction. J Neuro-Ophthalmol. 2017; **37**: 17-23.
19. **Aguilar-Perez M, Martinez-Moreno R, Kurre W, Wendl C, Bazner H, Ganslandt O, Unsold R, Henkes H.** Endovascular treatment of idiopathic intracranial hypertension: retrospective analysis of immediate and long-term results in 51 patients. Neuroradiology, 2017 Mar; **59 (3)**: 277-287. Doi: 10.1007/s00234-017-1783-5.
20. **Chang RO, Marshall BK, Yahyavi N, Sharma A, Huecker J, Gordon MO, et al.** Neuroimaging Features of Idiopathic Intracranial Hypertension Persist After Resolution of Papilloedema. Neuro-Ophthalmology, 2016; **40 (4)**: 165-170. DOI: 10.1080/01658107.2016.1179767.
21. **Ge M, Li S, Wang L, Zhang J.** The role of diffusion tensor tractography in the surgical treatment of pediatric optic chiasmatic gliomas. J Neurooncol. 2015; **122 (2)**: 357-66. Doi: 10.1007/s11060-015-1722-4.
22. **Smitha JH, Garrityb JA, Boesc CJ.** Clinical features and long-term prognosis of trochlear headaches. Eur J Neurol. 2014; **21**: 577-585.
23. **Balk LJ, Steenwijk MD, Tewarie P, Daams M, Killestein J, Watties MP, et al.** Bidirectional trans-synaptic axonal degeneration in the visual pathway in multiple sclerosis. J Neurol Neurosurg Psychiatry, 2015; **86 (4)**: 419-24. Doi: 10.1136/jnnp-2014-308189.
24. **de Blank PMK, Berman JI, Liu GT, Roberts TPL, Fisher MJ.** Fractional anisotropy of the optic radiations is associated with visual acuity loss in optic pathway gliomas of neurofibromatosis type 1. Neuro-Oncology, **15 (8)**: 1088-1095, 2013.
25. **Mehta S, Loevner LA, Mikityansky I, Langlotz C, Ying GS, Tamhankar MA, Shindler KS, Volpe NJ.** The Diagnostic and Economic Yield of Neuroimaging in Neuro-ophthalmology. J Neuro-Ophthalmol. 2012; **32**: 139-144. Doi: 10.1097/WNO.0b013e31824e3753.
26. **Ambika S, Arjundas D, Noronha V, Anshuman.** Clinical profile, evaluation, management and visual outcome of idiopathic intracranial hypertension in a neuro-ophthalmology clinic of a tertiary referral ophthalmic center in India. Ann Indian Acad Neurol.

- 2010; **13**: 37-41. DOI: 10.4103/0972-2327.61275.
27. **Agarwal P, Kumar M, Arora V.** Clinical profile of cerebral venous sinus thrombosis and the role of imaging in its diagnosis in patients with presumed idiopathic intracranial hypertension. *Indian J Ophthalmol.* 2010; **58**: 153-155. DOI: 10.4103/0301-4738.60092.
 28. **Wolfe S, Stavern GV.** Characteristics of patients presenting with ocular pain. *Can J Ophthalmol.* 2008; **43**: 432-4. Doi: 10.3129/i08-083.
 29. **Lee AG, Chau FY, Golnik KC, Kardon RH, Wall M.** The Diagnostic Yield of the Evaluation for Isolated Unexplained Optic Atrophy. *Ophthalmology.* 2005; **112** (5): 757-759.
 30. **Mcfadzean RM, Teasdale EM.** Computerized tomography angiography in isolated third nerve palsies. *J. Neurosurg.* 1998; **88**: 679-684.
 31. **Jacobson DM.** The Localizing Value of a Quadrantanopia. *Arch Neurol.* 1997; **54**: 401-404.
 32. **Go JA, Othman B, Kini A, Beaver HA, Lee AG.** Vertebrobasilar ischemia (VBI) related neuro-ophthalmic syndromes after routine activities involving hyperextension or rotation of the neck (hairdresser syndrome). *Eye.* 2019. <https://doi.org/10.1038/s41433-019-0611>.
 33. **Tommy LH, Chan TLH, Kim DD, Sharma M, Lee DH, Fraser JA.** Valsalva-triggered pseudotumor cerebri syndrome. Case series and pathogenetic implications. *Neurology.* 2018; **91**: e746-e750. Doi:10.1212/WNL.0000000000006048.
 34. **Karti DT, Karti O, Celebisoy N.** A rare cause of Horner's syndrome: cervicothoracic spinal root cysts. *Neurol Sci.* 2019; **40** (6): 1311-1314. Doi: 10.1007/s10072-019-03773-y.
 35. **Ravindran K, Schmalz P, Torun N, Ronthal M, Chang YM, Thomas AJ.** Angiographic Findings in the Tolosa-Hunt Syndrome and Resolution after Corticosteroid Treatment. *Neuro-Ophthalmology.* 2018; **42** (3): 59-163. DOI: 10.1080/01658107.2017.1365268.
 36. **Baartman BJ, Adamopoulou C.** Isolated Abducens Palsy Heraldng Occult Human Immunodeficiency Virus-Related Lymphoma. *Neuro-Ophthalmology.* 2017; **42** (1): 31-34. DOI: 10.1080/01658107.2017.1321677.
 37. **NadhaA, Williams ES.** New migraine with visual disturbance after cryoballoon ablation of atrial fibrillation. *J Atr Fibrillation.* 2017; **10** (3): 1646.
 38. **Dumitrascu OM, Okazaki EM, Cobb SH, Zarka MA, De Souza SA, Kumar G, O'Carroll CB.** Amyloid-Beta-Related Angiitis with Distinctive Neuro-Ophthalmologic Features. *Neuro-Ophthalmology.* 2017. DOI: 10.1080/01658107.2017.1374982.
 39. **Chou MC, Lee CY, Chao SC.** Temporary Visual Loss Due to Posterior Reversible Encephalopathy Syndrome in the Case of an End-Stage Renal Disease Patient. *Neuro-ophthalmology.* 2018; **42** (1): 35-39.
 40. **Yuen CA, Pula JH, Mehta M.** Primary Ocular Adnexal Extranodal Marginal Zone Mucosa-Associated Lymphoid Tissue (MALT) Lymphoma Presenting as Orbital Apex Syndrome. *Neuro-Ophthalmology.* 2017; **41** (2): 94-98. DOI: 10.1080/01658107.2016.1263343.
 41. **Oku H, Miyachi S, Ikeda T.** One-Sided Headache Is a Symptom Suggesting Aneurysmal Lesion in Patients with Isolated Abducens Nerve Palsy. *Neuro-Ophthalmology.* 2017; **41** (1): 35-38. DOI: 10.1080/01658107.2016.1246573.
 42. **Raof N, Batty R, Carroll TA, Pepper IM, Sandison A, Eckersley R, Hickman SJ.** Relapsing-Remitting Sixth Nerve Palsy in Association with Ollier's Disease. *Neuro-Ophthalmology.* 2015; **39** (2): 92-95.
 43. **Kleffner I, Wessling C, Gess B, Korsukewitz C, Allkemper T, Schirmacher A, et al.** Behr syndrome with homozygous C19ORF12 mutation. *J Neurol Sci.* 2015; **357** (1-2): 115-8. Doi: 10.1016/j.jns.2015.07.009.
 44. **Vaphiades MS, Visscher K, Rucker JC, Vattoth S, Roberson GH.** Functional Magnetic Resonance Imaging (MRI) and MRI Tractography in Progressive Supranuclear Palsy-Like Syndrome. *Neuro-Ophthalmology.* 2015; **39** (2): 64-68.
 45. **Koukkoulli A, Koutroumanos N, Kidd D.** Perineural Spread of Cutaneous Squamous Cell Carcinoma Manifesting as Ophthalmoplegia. *Neuro-Ophthalmology.* 2015; **39** (3): 144-146. DOI: 10.3109/01658107.2015.1035449.
 46. **Cheng HC, Yen MY, Wang AG.** Neuroimaging and clinical features of patients with optic nerve hypoplasia in Taiwan. *Taiwan J Ophthalmol.* 2015 Jan-Mar; **5** (1): 15-18. Doi: 10.1016/j.tjo.2014.11.001.
 47. **Madgula IM, Hemmerdinger CM, Clark P.** Metastatic breast cancer presenting as sequential cranial nerve palsy: a case report. *Journal of Medical Case Reports.* 2014; **8**: 430.
 48. **Berkenstock M, Szeles A, Ackert J.** Encephalopathy, Chiasmal Compression, Ophthalmoplegia and Diabetes Insipidus in Pituitary Apoplexy. *Neuro-Ophthalmology.* 2014; **38** (5): 286-289.
 49. **Bansal S, Yin K, Vishwanath M, Doran H, Laitt R, Ansons A.** Isolated Pupil-Involving Third Nerve Palsy as the First Presentation of Sarcoidosis. *Neuro-Ophthalmology.* 2014; **38** (5): 278-280.
 50. **Rosini F, Pretegianni E, Guideri F, Cerase A, Rufa A.** Eight and a Half Syndrome with Hemiparesis and Hemihypesthesia: The Nine Syndrome? *Journal of Stroke and Cerebrovascular Diseases.* 2013; **22** (8): e637-e638.
 51. **Pehera N, Anjaneyulu C, Mittal R, Vemuganti G.** Compressive Optic Neuropathy Caused by a Cholesterol Granuloma of the Sphenoidal Sinus. *Neuro-ophthalmology.* 2011; **35** (2): 78-80.
 52. **Reyes KB, Goh KY, Cullen JF.** Glare in a Case of a Craniopharyngioma. *Neuro-ophthalmology.* 2011; **35** (2): 73-75.

53. **Raghavendra S, Vasudha K, Shankar RS.** Isolated trochlear nerve palsy with midbrain hemorrhage. *Indian J Ophthalmol.* 2010; **58**: 66-67. DOI: 10.4103/0301-4738.58476.
54. **Asensio-Sánchez VM, Torreblanca-Agüera B, Martínez-Calvo S, Calvo MJ, Rodríguez R.** Visual symptoms as the first manifestation of Alzheimer's disease. *Arch Soc Esp Oftalmol.* 2006; **81**: 169-172.
55. **Lee AG, Martin CO.** Neuro-ophthalmic Findings in the Visual Variant of Alzheimer's Disease. *Ophthalmology*, 2004; **111**: 376–381.
56. **Freedman KA, Polepalle S.** Transient Homonymous Hemianopia and Positive Visual Phenomena in Nonketotic Hyperglycemic Patients. *Am J Ophthalmol.* 2004; **137**: 1122–1124.
57. **Tamhankar MA, Liu GT, Young TL, Sutton LN, Hurst RW.** Acquired, Isolated Third Nerve Palsies in Infants with Cerebrovascular Malformations. *Am J Ophthalmol.* 2004; **138** (3): 485-486.
58. **Parsa CF, Hoyt CS, Lesser RL, Weinstein JM, Strother CM, Mendoza RM et al.** Spontaneous Regression of Optic Gliomas: Thirteen Cases Documented by Serial Neuroimaging. *Arch Ophthalmol.* 2001; **119** (4): 516–529.
59. **Lee AG, Lin DJ, Kaufman M, Golnik KC, Vaphiades MS, Eggenberger E.** Atypical features prompting neuroimaging in acute optic neuropathy in adults. *Can J Ophthalmol.* 2000; **35**: 325-30.
60. **Moster ML, Johnson MH.** A neuro-ophthalmologist's perspective on Neuro-radiology. *Seminars in Ultrasound, CT and MRI*, 1998; **19** (3): 216-225.

