

Intracameral Versus Sub-conjunctival Dexamethasone Injection for Postoperative Inflammation in Congenital Cataract Surgery

Afia Matloob Rana, Ali Raza, Waseem Akhter

Pak J Ophthalmol 2019, Vol. 35, No. 3

.....
See end of article for authors affiliations
.....

Correspondence to:
Afia Matloob Rana
Assistant Professor
Ophthalmology Department
HBS General Hospital,
Islamabad
Email: afiamatloob@yahoo.com

Purpose: To compare the effect of intracameral with sub-conjunctival injection of dexamethasone in preventing immediate postoperative inflammation after congenital cataract extraction.

Study Design: Randomized control trial.

Place and Duration of Study: Holy Family Hospital, Rawalpindi from June 2014 to May 2015.

Material and Methods: All Pediatric patients less than 15 years of age and of both genders, undergoing cataract surgery in Holy Family Hospital, were included in the study using a random table. Using standardized sample size calculator and statistical assumption with 95% CI and 5% alpha error, the study sample was 95 cases in each group. Group A patients got intracameral injection of dexamethasone while Group B patients got subconjunctival injection of dexamethasone. The outcome measure was intraocular inflammation after cataract surgery. Examination was done within first three postoperative days for signs of anterior chamber inflammation. Standard slit lamp or hand held slit lamp was used for this purpose.

Results: One hundred and ninety patients were included in the study. The patients were equally divided into 2 groups. Male cases were in majority in group B (58.9%) whereas in group A females (55.8%) were in majority. Mean age was 6.43 ± 4.69 years in Group-A compared to 5.85 ± 4.10 years in Group-B. Frequency of posterior synechiae (inflammation) was 4.21% (n = 4) in Group-A (intracameral) compared to 15.79% (n = 15) in Group-B (subconjunctival) which was significantly different (p-value = 0.007).

Conclusion: Intracameral injection is better than sub-conjunctival injection of dexamethasone in the management of post-operative inflammation in children with congenital cataract.

.....
Keywords: Congenital cataract, Dexamethasone, Injections, Inflammation.

Cataract is one of the leading causes of blindness worldwide. It accounts for nearly half (47.8%) of the total 17.7 million cases of blindness¹. Pakistani population is also getting equally affected from cataract, with high prevalence².

The partial or complete blindness is mainly affecting the elder population and reducing their quality of life by making them dependent on others and posing economic burden on communities and the country^{2,3}. Nevertheless, cataract affects all age groups

but comparatively it is less common in children. VISION 2020 the 'Right to Sight' is the main initiative program to control the visual deterioration and ultimate lasting blindness among children of developing countries.³ Lifelong impact of cataract in childhood is very large considering the potential lifespan of a child⁴.

Congenital Cataract is cloudiness of the crystalline lens of the eye, which is present at birth and is mostly bilateral, clinically present with decreased vision or white reflex. It is diagnosed on slit-lamp biomicroscopy of the anterior segment of the eye. It can present in any form like nuclear, lamellar, sutural, coronary, polar and membranous cataract. The most common presentation is the nuclear cataract⁵.

The treatment for visually significant cataract is surgical, a highly cost effective intervention, with excellent prognosis for sight restoration. Early management of congenital cataract prevents the child from developing amblyopia and ensures good visual outcome⁶.

Congenital cataract surgery can result in complications like posterior capsule opacification, glaucoma and retinal detachment⁷. Most common post operative complication in congenital cataract is inflammation⁸. Inflammation can lead to complications like peripheral anterior synechiae, posterior synechiae, exudative membrane and pupil block glaucoma, thus hampering good visual rehabilitation. The rationale of the study was to find a treatment option which would reduce the post-operative inflammation and prevent complications.

Intensive conventional topical steroid treatment is still main trusted mode of managing inflammation, along with other available options, like sub-conjunctival injection during surgery, collagen shield, intracameral injection and sustained release intraocular drug delivery system^{9,10}.

There are various therapeutic options for inflammation with different levels of efficacy and safety. We planned a study with the purpose of comparing the role of intracameral injection with sub-conjunctival injection of dexamethasone in preventing immediate postoperative inflammation after congenital cataract extraction.

MATERIAL AND METHODS

A randomized controlled trial was conducted at the department of ophthalmology, Holy Family Hospital,

Rawalpindi for a period of one year from June 2014 to May 2015. Using standardized sample size calculator and statistical assumption with 95% CI and 5% alpha error, the study sample was 95 cases in each group. It was hypothesized that Intracameral injection of 0.5 ml (2 mg) dexamethasone reduces immediate postoperative inflammation after surgery for congenital cataracts. A total of 190 children with cataract were enrolled (WHO calculator), using a random table, 95 cases each in intra-cameral injection and sub-conjunctival injection groups.

Children less than 15 years and of both genders were enrolled. Visually significant congenital cataract was determined by Snellen's visual acuity of < 6/6 for verbal child and cataract size more than 3 mm in the area of visual axis, obscuring fundal glow for non-verbal child. Cases with no associated anterior or posterior segment pathology were selected. Patients with secondary cataract, prior ocular surgery and per operative complication e.g. posterior capsular rent, nucleus drop were excluded from the study.

All the children were operated for aspiration of the lens, primary posterior surgical capsulotomy and anterior vitrectomy. Children below age of two years were operated without intraocular lens implantation while above two years with intraocular lens implantation. In group A, patients were given intracameral dexamethasone injection 0.5 ml (2 mg) and 0.5 ml (20 mg) gentamycin injection in sub-conjunctival area. In group B, 0.5 ml (2 mg) dexamethasone and 0.5 ml (20 mg) gentamycin injection were given in the sub-conjunctival space at the end of surgery.

Examination was done within first three postoperative days, for signs of immediate anterior chamber inflammation, by standard slit lamp or hand held slit lamp. In case of non-cooperative children, examination was done with hand held slit lamp under sedation or general anesthesia for posterior synechiae. Postoperatively all patients were given topical dexamethasone suspension (1 drop after every 1 hour), tobramycin eye drops (one drop after every 2 hours), 1% cyclopentolate eye drops (one drop after every 8 hours) for one week.

The study outcome was measured in terms of efficacy of intracameral injection and subconjunctival injection of dexamethasone in the treatment of inflammation after surgery of congenital cataract.

The data was entered and analyzed in SPSS version 20.0. Continuous variable like age was presented as Mean and SD. The categorical variables

like gender, inflammation (posterior synechiae) was analyzed as frequency and percentages and compared between the two groups using chi-square test, a p-value of < 0.05 was taken as significant.

RESULTS

One hundred and ninety cases (95 in each group) fulfilling the inclusion/exclusion criteria were enrolled to intracameral injection or sub-conjunctival injection of dexamethasone to see their effect on postoperative inflammation in congenital cataracts.

Age distribution of the cases showed that majority of the cases were within 1-10 years of age. In group A there were 73.68% (n = 70) patients and in Group-B there were 78.95% (n = 75). The results of age

distribution are shown in Table 1.

The gender distribution showed that there was nearly equal distribution among males and females. The results of gender distribution are shown in Figure 1.

Comparison of the Intracameral injection with sub-conjunctival injection of Dexamethasone in terms of frequency of posterior synechiae (inflammation) was recorded which showed that 4.21% (n = 4) in Group-A and 15.79% (n = 15) in Group-B had posterior synechiae while remaining 95.79% (n = 91) in Group-A and 84.21% (n = 80) in Group-B had no findings of the morbidity. This difference in the incidence of inflammation post operatively was found statistically significant between the two groups (p-value, 0.007) (Table 2).

Table 1: Age Distribution (n = 190).

Age (in Years)	Intracameral Injection Group (A) (n = 95)		Subconjunctival Injection Group (B) (n = 95)	
	No. of patients	%	No. of patients	%
1 - 10	70	73.68	75	78.95
11 - 15	25	26.32	20	21.05
Mean ± SD	6.43 ± 4.69		5.86 ± 4.10	

Table 2: Comparison of Posterior Synechiae between the Two Study Groups (n = 190).

Inflammation (Posterior Synechiae)	Intracameral Injection Group (A) (n = 95)		Subconjunctival Injection Group (B) (n = 95)		p-value
	No. of patients	%	No. of patients	%	
Yes	4	4.21	15	15.79	0.007
No	91	95.79	80	84.21	

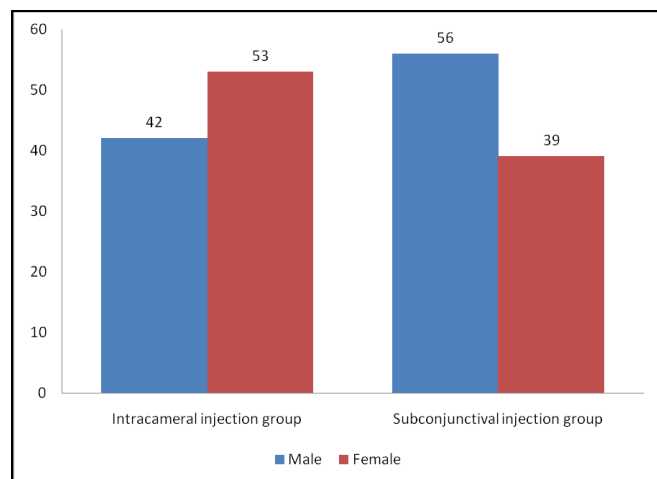


Fig. 1: Gender distribution in both study groups (n = 190).

DISCUSSION

Congenital cataract is an important reason of visual impairment among children, throughout the world and 5%-20% of blindness in children is because of congenital cataract^{11,12}. All over the world 1.4 million children are blind and blindness in 190,000 children is because of cataract¹³. Congenital cataract presents either since birth or shortly after birth^{14,15}. In Asia 1 million children are blind because of congenital cataracts¹⁶. The estimated prevalence of cataract among children is 3 in 10,000 live births¹⁷.

Surgical option is the main management strategy in these conditions, which is successful, however, some side effects also worries the patients. Ocular inflammation is one such complaint. The peri-operative use of anti-inflammatory therapy has well

established role in standard cataract surgery. The aim is to treat postoperative intraocular inflammation and enhance patient's comfort. Different anti-inflammatory agents are used according to the patient's need and surgeon's preferences¹⁸.

In the present study posterior synechiae were recorded in 4.21% cases in Group-A and 15.79% in Group-B, and the difference was statistically significant (p-value, 0.007). Our findings regarding significantly greater success of intracameral dexamethasone are in accordance with many previous studies. A study by Iqbal and colleagues reported that dexamethasone when injected intracamerally increased its efficacy by about 5% as compared to subconjunctival route¹⁹. Ahmad et al who evaluated the role of subconjunctival and intracameral dexamethasone found that the later had better results and concluded that intracameral injection of dexamethasone was superior to sub-conjunctival injection of dexamethasone in preventing immediate postoperative anterior uveitis²⁰. Another recent study evaluated the effect of intracameral dexamethasone on corneal endothelium, and concluded that the use of intracameral dexamethasone at the end of cataract surgery is safe for corneal endothelium²¹. The study by Zhang et al demonstrated that the average inflammation score was significantly lower in Dexamethasone group compared with the Indomethacin and Ciprofloxacin groups. Moreover, they also witnessed decreased intra-ocular pressure with Dexamethasone compared to other study interventions²².

Our findings are in agreement with the above body of evidence, which is justifying the hypothesis that "Intracameral injection of 0.5 ml (2 mg) dexamethasone reduces immediate postoperative inflammation after surgery for congenital cataracts", Intracameral injection may be used for better management of postoperative inflammation following congenital cataract extraction.

Limitation of the study was that it was a single center study, which was focused on early postoperative results. Further study needs to be done to evaluate long term results of this intervention at multiple centers.

CONCLUSION

Intracameral injection of dexamethasone is significantly better than subconjunctival injection in terms of frequency of early postoperative

inflammation in congenital cataracts. This leads to better visual rehabilitation.

REFERENCES

1. Rao GN, Khanna R, Payal A. The global burden of cataract. *Curr Opin Ophthalmol*. 2011; 22: 4-9.
2. Jadoon Z, Shah SP, Bourne R, Dineen B, Khan MA, Gilbert CE. Cataract prevalence, cataract surgical coverage and barriers to uptake of cataract surgical services in Pakistan: the Pakistan National Blindness and Visual Impairment Survey. *Br J Ophthalmol*. 2007; 91: 1269-73.
3. Sheeladevi S, Lawrenson JG, Fielder AR, Suttle CM. Global prevalence of childhood cataract: a systematic review. *Eye (Lond)*. 2016; 30: 1160-69.
4. Courtright P, Hutchinson AK, Lewallen S. Visual impairment in children in middle- and lower-income countries. *Arch Dis Child*. 2011; 96: 1129-34.
5. Hoffman RS, Braga-Mele R, Donaldson K, Emerick G, Henderson B, Kahook M et al. Cataract surgery and nonsteroidal anti-inflammatory drugs. *J Cat Refract Surg*. 2016; 42: 1368-1379.
6. Chan WH, Biswas S, Ashworth JL, Lloyd IC. Educational paper: Congenital and infantile cataract: etiology and management. *Eur J Pediatr*. 2012; 171: 625-30.
7. Kuhli HC, Lüchtenberg M, Kohnen T, Hattenbach LO. Risk factors for complications after congenital cataract surgery without intraocular lens implantation in the first 18 months of life. *Am J Ophthalmol*. 2008; 146: 1-7.
8. Huang Y, Dai Y, Wu X, Lan J, Xie L. Toxic anterior segment syndrome after pediatric cataract surgery. *J Am Acad Ped Ophthalmol Strabismus*, 2010; 14: 444-6.
9. Chang DT, Herceg MC, Bilonick RA, Camejo L, Schuman JS, Noecker RJ. Intracameral dexamethasone reduces inflammation on the first postoperative day after cataract surgery in eyes with and without glaucoma. *Clin Ophthalmol*. 2009; 3: 345-55.
10. Dieleman M, Wubbels RJ, Kooten-Noordzij M, deWaard PW. Single perioperative subconjunctival steroid depot versus postoperative steroid eye drops to prevent intraocular inflammation and macular edema after cataract surgery. *J Cataract Refract Surg*. 2011; 37: 1589-97.
11. Halilbasic M, Zvornicanin J, Jusufovic V, et al. Pediatric cataract in Tuzla Canton, Bosnia and Herzegovina. *Med Glas (Zenica)*. 2014; 11: 127-31.
12. Santhiya ST, Kumar GS, Sudhakar P, Gupta N, Klopp N, Illig T, etc. Molecular analysis of cataract families in India: new mutations in the CRYBB2 and GJA3 genes and rare polymorphisms. *Mol Vis*. 2010; 16: 1837-47.
13. Randrianotahina HC, Nkumbe HE. Pediatric cataract surgery in Madagascar. *Niger J Clin Pract*. 2014; 17: 14-7.
14. Nkumbe HE, Randrianotahina HC. Meeting the need for childhood cataract surgical services in Madagascar.

- Afr J Paediatr Surg. 2011; 8: 182-4.
15. **Bronsard A, Geneau R, Shirima S, Courtright P, Mwende J.** Why are children brought late for cataract surgery? Qualitative findings from Tanzania. *Ophthalmic Epidemiol.* 2008; 15: 383-8.
 16. World Health Organisation. Prevention of childhood blindness. Geneva: WHO; 1992.
 17. **Sana N, Muhammad A, Humaira F.** Congenital Cataract: Morphology and Management *Pak J Ophthalmol.* 2013; 29: 151-55.
 18. **Aptel F, Colin C, Kaderli S, Deloche C, Bron AM, Stewart MW, Chiquet C.** OSIRIS group. Management of postoperative inflammation after cataract and complex ocular surgeries: a systematic review and Delphi survey. *Br J Ophthalmol.* 2017; 101: 1-10.
 19. **Iqbal CJ, Ali Z, Ahmad KA, Akram MA.** Comparison of intracameral dexamethasone and subconjunctival dexamethasone in reducing postoperative inflammation after cataract surgery. *Ophthalmol Pak.* 2011; 1: 8-11.
 20. **Ahmad CN, Khan AA, Siddique Z, Ahmed S.** Role of Intracameral Dexamethasone in Preventing Immediate Postoperative Anterior Uveitis in Paediatric Cataract Extraction. *Pak J Med Health Sci.* 2010; 4: 338-42.
 21. **Jamil AZ, Ahmed A, Mirza KA.** Effect of Intracameral Use of Dexamethasone on Corneal Endothelial Cells. *J Coll Phys Surg Pak.* 2014; 24: 245-8.
 22. **Zhang G, Liu S, Yang L, Li Y.** The role of Dexamethasone in clinical pharmaceutical treatment for patients with cataract surgery. *Experiment Therap Med.* 2018; 15: 2177-2181.

Author's Affiliation

Dr. Afia Matloob Rana

MBBS, FCPS

Assistant Professor; Ophthalmology

HBS general Hospital, Islamabad. Pakistan

Dr. Ali Raza

MBBS; MCPS; FCPS

Professor; Ophthalmology

Holy Family Hospital. Rawalpindi Pakistan

Dr. Waseem Akhter

MBBS; MCPS; FCPS

Associate Professor; Ophthalmology

Rawal Institute of Health Sciences, Islamabad

Author's Contribution

Dr. Afia Matloob Rana

Data collection, Preoperative and postoperative patient evaluation, Assistance during surgeries of patients, included in the study

Dr. Ali Raza

Surgeon performed the surgeries upon the study cases, Helped in preoperative and post-operative evaluation to the primary author

Dr. Waseem Akhter

Final compilation of data, Preparation of SPSS data sheets, Data analysis, Paper writing