

Association of Intima-media Thickness of Internal Carotid Artery with Ocular Pseudoexfoliation

Oguz Guvenmez, Asim Kayiklik

Pak J Ophthalmol 2019, Vol. 35, No. 1

.....
See end of article for authors affiliations
.....

Correspondence to:
Oguz Guvenmez, MD
Special Internal Medicine Clinic,
Adana, Turkey
E-mail:
oguzguvenmez001@hotmail.com

Purpose: To compare the internal carotid artery intima-media thickness (CAIMT) in patients with ocular PEX and healthy controls and to show that ocular PEX may be related to atherosclerosis, or not.

Study Design: Cross-sectional study.

Place and Duration of Study: Department of Ophthalmology in Adana Ortadogu Hospital, Adana, Turkey. The study was conducted between January 2017 and January 2018.

Material and Methods: There were 32 participants in the study. In the biomicroscopic anterior segment examination, 16 patients were diagnosed with pseudoexfoliative material on the pupil margin or anterior lens capsule. These patients formed the first group (Group I). 16 non-PEX patients were accepted as a control group (Group II). Patients with systemic disease such as hypertension, diabetes mellitus were excluded from the study. CAIMT was measured and noted in all participants. Carotid artery Doppler USG was used to measure CAIMT. The data were compared by statistical analysis.

Results: In Group I and Group II, the age of the patients did not differ significantly ($p > 0.05$). In Group I and Group II, gender distribution was not significant ($p > 0.05$). In Group I, CAIMT was significantly higher than in Group II ($p < 0.05$).

Conclusion: Ocular PEX appears to be associated with atherosclerosis.

Keywords: Ocular pseudoexfoliation, atherosclerosis, carotid artery.

.....
Atherosclerosis, a systemic vascular disease, is a progressive common health problem all over the world¹. This disease may not show any clinical symptoms, but it can be a sign of serious disease².

Atherosclerosis is a phenomenon of dysfunction in the endothelial cells and accumulation of some substances in tunica intima.³ These substances include lipoprotein particles. They are foamy macrophage cells resulting from the collection of leukocytes. Thus, smooth muscle cells in the tunica media begin to form atheroma plaques^{4,5}. This may lead to both

cardiovascular disease and pseudoexfoliation syndrome⁶.

Ocular pseudoexfoliation (PEX) is the detection of fibrillar extracellular matrix accumulation on the anterior segment of the lens, pupil circumference, iris epithelium or zonules during the anterior segment examination⁷. The mechanism and the etiology of PEX formation has not been fully understood. Furthermore, the relationship of ocular PEX with systemic diseases has been demonstrated in various studies⁸⁻¹⁴.

Many diseases can be diagnosed early with internal carotid artery intima media thickness

(CAIMT).⁹ Ultrasonography technique is an inexpensive, easy and non-invasive method through which intima media thickness is measured¹⁰. Many studies have been conducted to measure intima media thickness in diabetics, obesity, and renal failure patients and dyslipidemia^{11,12}.

The aim of this study is to compare the internal carotid artery intima-media thickness (CAIMT) in patients with ocular PEX and healthy individuals, and to show that ocular PEX may be related to systemic diseases such as atherosclerosis, or not.

MATERIAL AND METHODS

Our study was a cross-sectional clinical study which included 32 patients with or without ocular PEX (40-80 years of age) who were admitted to the Department of Ophthalmology in Adana Ortadogu Hospital between January 2017 and January 2018. The patients were admitted to our clinic with the complaint of low vision. The ethical approval was obtained from the ethics committee of Adana City Hospital in Adana in Turkey and informed consent was obtained from the all participants.

In the biomicroscopic anterior segment examination, 16 patients were diagnosed with pseudoexfoliative material on the pupil margin or anterior lens capsule. These patients formed the first group (Group I). Other 16 non-PEX patients were accepted as a control group (Group II). Patients with systemic disease such as hypertension, diabetes mellitus were excluded from the study.

CAIMT was measured and noted in all participants. Carotid artery Doppler USG was used to measure CAIMT. The data was compared by statistical analysis. Mean, standard deviation, median lowest, highest, frequency and ratio values were used in descriptive statistics of the data. The distribution of the variables was measured with the Kolmogorov-Smirnov Test. Independent Sample T Test was used

to analyze the quantitative independent data. χ^2 test was used for the comparison of normally distributed categorical variables. SPSS 22.0 program was used in the analysis.

RESULTS

The demographic variables of the sample are presented in Table 1. In Group I and Group II, the age of the patients did not differ significantly ($p > 0.05$). In Group I and Group II, gender distribution was not significant ($p > 0.05$). In Group I, CAIMT was significantly higher than in Group II ($p < 0.05$) (table 2 and figure 1).

Table 1: Demographic variables of the sample.

	Min-Max	Median	Mean \pm SD/N%
Age	43.0 – 78.0	64.0	61.2 \pm 9.7
Sex	Male		16 50%
	Female		16 50%

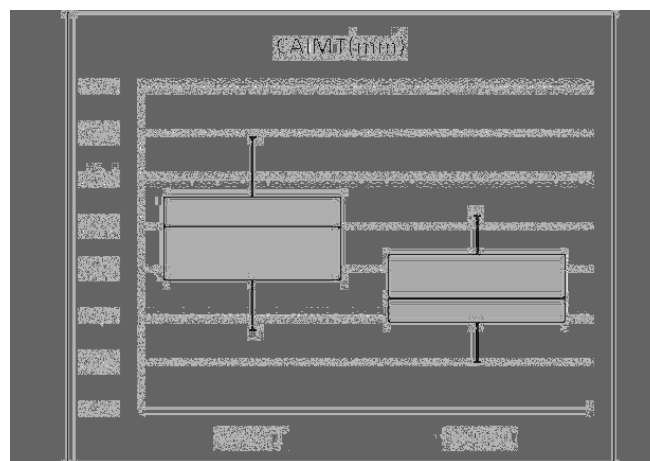


Fig. 1: The comparison of CAIMT between the groups.

Table 2: The comparison of Group I and Group II.

	Group 1		Group 2		P
	Mean \pm SD/N%	Median	Mean \pm SD/N%	Median	
Age	61.5 \pm 9.6	64.0	60.8 \pm 10.2	64.0	0.845
Sex	Male	9 56.3%	7 43.8%		0.480
	Female	7 43.8%	9 56.3%		
CAIMT (mm)	0.77 \pm 0.12	0.80	0.66 \pm 0.09	0.64	0.004

DISCUSSION

Pseudoexfoliation syndrome (PEXS) is a clinically diagnosed disease and its etiopathogenesis has not been determined yet. However, there are studies showing that there is a relationship between PEXS and systemic diseases. In addition, PEX is a common age-related systemic metabolic vascular disease affecting the elastin microfibrillar tissue. It is characterized by white grey extracellular flaky material in the anterior segment.¹⁵ According to microscopic findings, PEX materials have been found in blood vessel wall, which could affect the function and elasticity of blood vessels, as shown by increased carotid artery stiffness¹⁶ and reduced brachial artery endothelial cell function¹⁷.

Schumacher et al. reported that five ocular PEX patients who were sampled from the aortic artery had significant PEX accumulation in the vessel intima media⁹. Cahill et al. conducted another study which demonstrated the systemic involvement of PEX. They showed the deposition of fibrilsin in the tectorial membrane of the inner ear. Bilateral sensorineural hearing loss was observed in the majority of patients with PEX, regardless of age and glaucoma¹⁸.

In a study in which the relationship between PEX and diabetes mellitus was investigated, there was no relationship between PEX and diabetes. In this study PEX etiopathogenesis was attributed to genetic and biochemical factors¹⁴. In a study by Ekström et al, the relationship between PEXS and aortic aneurysm was investigated, but no association was found between the two diseases^{19,20}.

Increased arterial wall thickness and changes in the vascular structure, expressed as CAIMT, have been identified as predictors of unexpected cardiovascular events. CAIMT has been shown to be an early marker of endothelial tissue damage and an early sign of atherosclerotic vascular disease^{21,22}.

CAIMT is highly correlated with the presence of coronary pathology and myocardial infarction. Carotid disease is seen in 30-60% of people with peripheral vascular disease. Approximately 50-60% of patients with carotid disease have advanced coronary disease, while only 10% of patients with coronary artery disease have advanced carotid disease²³. Therefore, we believe that early detection of increased CAIMT will have an important role in prevention of cardiological and neurological diseases.

CONCLUSION

There is a positive link between CAIMT and ocular PEX in our study. Since CAIMT is associated with atherosclerosis, there may also be an association between ocular PEX and atherosclerosis. In this context, with a simple eye examination, it can be learned whether the patients have a risk of coronary artery disease, or not. This may also help in the early diagnosis of atherosclerosis. However, future studies pointing this subject are needed to clarify these findings.

Conflict of Interests

All authors declare that they have no conflict of interests.

Author's Affiliation

Oguz Guvenmez, MD
Special Internal Medicine Clinic, Adana, Turkey.

Asim Kayiklik, MD
Department of Ophthalmology, Adana Ortadogu Hospital, Adana, Turkey.

Author's contribution

Oguz Guvenmez, MD
Study Design, interpreting results, writing manuscript.

Asim Kayiklik, MD
Collecting data, Statistical analysis, writing manuscript.

REFERENCES

1. **Ross R.** Atherosclerosis. In: McGee J, Isaacson PG, Wright NA, editors. Oxford Textbook of Pathology. Vol. 2, Oxford: Oxford University Press; 1992: 798-812.
2. **McGill HC Jr, McMahan CA.** Determinants of atherosclerosis in the young. Pathobiological Determinants of Atherosclerosis in Youth (PDAY) Research Group. Am J Cardiol. 1998; 82: 30-6.
3. **Rafieian-Kopaei M, Setorki M, Doudi M, Baradaran A, Nasri H.** Atherosclerosis: process, indicators, risk factors and new hopes. Int J Prev Med. 2014; 5: 927-46.
4. **Kuller L, Borhani N, Furberg C, Gardin J, Manolio T, O'Leary D, et al.** Prevalence of subclinical atherosclerosis and cardiovascular disease and association with risk factors in the Cardiovascular Health Study. Am J Epidemiol. 1994; 139: 1164-79.
5. **Touboul PJ, Hennerici MG, Meairs S, Adams H, Amarenco P, Bornstein N, et al.** Mannheim carotid intima-media thickness consensus (2004-2006). An

- update on behalf of the Advisory Board of the 3rd and 4th Watching the Risk Symposium, 13th and 15th European Stroke Conferences, Mannheim, Germany, 2004, and Brussels, Belgium, 2006. *Cerebrovasc Dis.* 2007; 23: 75-80.
6. **Siordia JA, Franco J, Golden TR, Dar B.** Ocular pseudoexfoliation syndrome linkage to cardiovascular disease. *Curr Cardiol Rep.* 2016; 18: 61.
 7. **Küchle M, Amberg A, Martus P, Nguyen NX, Naumann GO.** Pseudoexfoliation syndrome and secondary cataract. *Br J Ophthalmol.* 1997; 81: 862-6.
 8. **Shrum KR, Hattenhauer MG, Hodge D.** Cardiovascular and cerebrovascular mortality associated with ocular pseudoexfoliation. *Am J Ophthalmol.* 2000; 129: 83-6.
 9. **Su TC, Chien KL, Jeng JS, Chen ME, Hsu HC, Torng PL, et al.** Age - and gender-associated determinants of carotid intima-media thickness: A community-based study. *J Atheroscler Thromb.* 2012; 19: 872-80.
 10. **Jaroch J, Loboż Grudzien K, Bociaga Z, Kowalska A, Kruszynska E, Wilczynska M, et al.** The relationship of carotid arterial stiffness to left ventricular diastolic dysfunction in untreated hypertension. *Kardiol Pol.* 2012; 70: 223-31.
 11. **Takiuchi S, Rakugi H, Fujii H, Kamide K, Horio T, Nakatani S, et al.** Carotid intima-media thickness is correlated with impairment of coronary flow reserve in hypertensive patients without coronary artery disease. *Hypertens Res.* 2003; 26: 945-51.
 12. **Schumacher S, Schlötzer-Schrehardt U, Martus P, Lang W, Naumann GO.** Pseudoexfoliation syndrome and aneurysms of the abdominal aorta. *The Lancet.* 2001; 3: 357: 359-60.
 13. **Rinvold A.** Pseudoexfoliation and aortic aneurysms. *The Lancet.* 2001; 357: 2139.
 14. **Psilas KG, Stefanidou MJ, Aspiotis MB.** Pseudoexfoliation syndrome and diabetes mellitus. *Acta Ophthalmol (Copenh).* 1991; 69: 664-6.
 15. **Streeten B, Gibson S, Dark A.** Pseudoexfoliative material contains an elastic microfibrillar-associated glycoprotein. *Trans Am Ophthalmol Soc.* 1986; 84: 304-20.
 16. **Visontai Z, Merisch B, Kollai M, Holló G.** Increase of carotid artery stiffness and decrease of baroreflex sensitivity in exfoliation syndrome and glaucoma. *Br J Ophthalmol.* 2006; 90: 563.
 17. **Naji M, Naji F, Suran D, Gracner T, Kanic V, Pahor D.** Systemic endothelial dysfunction in patients with pseudoexfoliation syndrome. *Klin Monbl Augenheilkd.* 2008; 225: 963-7.
 18. **Cahill M, Early A, Stack S, Blayney AW, Eustace P.** Pseudoexfoliation and sensorineural hearing loss. *Eye.* 2002; 16: 261-6.
 19. **Ekström C, Wilger S, Wanhainen A.** Pseudoexfoliation and aortic aneurysm: a long-term follow-up study. *Acta Ophthalmol.* 2019; 97 (1): 80-83.
 20. **Besir FH, Yazgan S, Celbek G, Aydın M, Yazgan Ö, Erkan ME, et al.** Normal values correlates of carotid intima-media thickness and affecting parameters in healthy adults. *Anadolu Kardiyol Derg.* 2012; 12: 427-33.
 21. **Mayet J.** Is carotid artery intima-media thickening a reliable marker of early atherosclerosis? *J Cardiovasc Risk.* 2002; 9: 77-81.
 22. **Jadhav UM.** Carotid intima media thickness as an independent predictor of coronary artery disease. *Indian Heart J.* 2001; 53: 458-62.
 23. **Magyar MT, Szikszai Z, Balla J, Valikovics A, Kappelmayer J, Imre S.** Early - onset carotid atherosclerosis is associated with increased intima - media thickness and elevated serum levels of inflammatory markers. *Stroke.* 2003; 34: 58-63.