

Pars Plana Vitreous Tap for Phacoemulsification in the Eyes with Crowded Anterior Segment

Irfan Qayyum Malik, Hafiza Sadia Imtiaz, Fazeela Shehzad

Pak J Ophthalmol 2018, Vol. 34, No. 2

See end of article for authors affiliations

Correspondence to:
Irfan Qayyum Malik
Eye Department of DHQ-
Teaching Hospital Gujranwala
Email: irfan790@yahoo.com

Purpose: To determine the efficacy of pars plana vitreous tap for safe accomplishment of phacoemulsification in eyes with severely crowded anterior segment.

Study Design: Quasi-experimental study.

Place and Duration of Study: Eye Department of DHQ-Teaching Hospital Gujranwala, from January 2014 to December 2017.

Material and Methods: Patients of both genders, above 40 years of age who had crowded anterior segments and in whom viscoelastic substance could not deepen the anterior chamber sufficiently during cataract surgery (phacoemulsification) were included in this study. All patients underwent phacoemulsification and pars-plana vitreous aspirate of 0.1 ml taken 4 mm from the limbus in supero-temporal quadrant using 27-gauge needle.

Results: 50 eyes of 40 patients with crowded anterior segment were included in this study. Sixteen (40%) were male and 24 (60%) were female. Average age noted was 54.3 ± 7.4 (range 48 – 65) years. Mean pre-op IOP recorded was 17.6 ± 2.3 (range 12 – 24.2) mm Hg, mean pre-op anterior chamber depth (ACD) of 2.1 ± 0.34 (range 1.6 – 2.6) mm and mean pre-op Axial length (AL) of 20.6 ± 0.45 (range 19.5 – 22.2) mm. Vitreous tap was successful in 42 eyes (84%) on first attempt and in remaining 8 eyes (16%), second attempt was required. Average volume of aspirated vitreous was 0.116 ± 0.03 (0.1 – 0.2) ml. The overall success rate was 100% with no per-op or post-op complications noted during follow up period of 6 months.

Conclusions: Vitreous tap using needle is simple, safe, efficient and cost-effective technique for management of shallow anterior chambers during phacoemulsification.

Key Words: Crowded anterior segment, axial length, anterior chamber depth, capsulorhexis, pars plana vitreous tap.

Yes with crowded anterior segments give a difficult time to the operating surgeon due to less working field and close proximity between lens and cornea, making capsulorhexis, phacoemulsification and IOL implantation quite tricky to perform. These eyes present with narrow angles and shallow anterior chambers¹.

Shallow anterior chamber can be with short axial

length or with normal axial length. Short axial length occurs in patients with microphthalmos (Simple or Complex) and nanophthalmos. Shallow anterior chamber with normal axial length (AL) can be with relative anterior microphthalmos, intumescent cataract, subluxated lens and in the presence of angle closure glaucoma².

Positive vitreous pressure can also lead to anterior

chamber shallowness during phacoemulsification. This positive vitreous pressure is precipitated by chronic obstructed pulmonary disease (COPD), constipation, obesity, systemic or ocular Hypertension and senility.

Risks encountered in such eyes during phacoemulsification include corneal endothelial damage due to close proximity of corneal endothelium with phaco tip, Descemet's membrane detachment, iris prolapse, capsulorhexis extension, Posterior capsular rent, vitreous haemorrhage and supra-choroidal haemorrhage³.

To encounter these challenging situations and to prevent associated risks, different methods were opted by ophthalmologists, which include pre-op use of dehydrating agents⁴, intra-operative use of ophthalmic viscoelastic device (OVD)⁵, pars-plana vitrectomy^{6,7,8} and pars-plana vitreous tap. Among all of these, pars-plana vitreous tap during phacoemulsification, in case of crowded anterior segment when viscoelastic substance fails to maintain anterior chamber, is found to be safe, easy and efficacious, as supported by various studies.

The rationale of our study was to determine the efficacy of pars-plana vitreous tap in making the anterior chamber deep thus allowing every step of cataract surgery to be carried out safely and effectively in these high risky eyes while keeping the advantages of a small incision.

MATERIAL AND METHODS

A Quasi-experimental study was conducted after approval from ethical and research committee of Gujranwala Medical College. Informed consent was taken from all those patients. Patients of both genders, above 40 years of age who had crowded anterior segments and in whom viscoelastic substance could not deepen the anterior chamber sufficiently during cataract surgery (phacoemulsification), were included in this study. Whereas patients younger than 40 years of age, patients with posterior segment pathologies such as vitreous haemorrhage, retinal detachment, malignant tumors and endophthalmitis were excluded from this study. It was carried out in 50 eyes of 40 patients at eye department of DHQ-Teaching Hospital Gujranwala from January 2014 to Dec. 2017.

Best corrected visual acuity (BCVA) using Snellen chart, IOP recording using Goldmann applanation tonometer, complete ophthalmic examination using slit lamp biomicroscopy, anterior chamber angle

assessment using Gonioscopy, anterior chamber depth (ACD) estimation using ultrasound A-scan and axial length (AL) measurement with the help of biometry was done pre-operatively. Eyes with crowded anterior segment were selected for pars-plana vitreous tap. The final decision to include patients in this study was made per-operatively when anterior chamber failed to deepen with viscoelastic substance.

Pupil was dilated with mydriatic eye drops. Surgery was carried out under retro-bulbar anaesthesia with 1% lignocaine and 0.5% bupivacaine followed by 10 minutes of external ocular massage. Supero-temporal or super-nasal corneal incision was given and anterior chamber was maintained with viscoelastic substance. Where there was failure to deepen the anterior chamber with viscoelastic gel, pars-plana vitreous tap was done using 27-gauge needle attached to 1 cc syringe, inserted 4 mm from limbus in supero-temporal quadrant and 0.1 ml of vitreous was removed. If the first attempt failed to aspirate vitreous fluid or if it was insufficient to adequately deepen the anterior chamber in spite of successful vitreous removal, a second vitreous tap was tried at the same site. Failure of the technique was defined as failure of two attempts to deepen the anterior chamber. When the anterior chamber was adequately deepened, continuous curvilinear capsulorhexis followed by hydro-dissection, phacoemulsification via chop technique, irrigation and aspiration of remaining cortical matter, IOL implantation in capsular bag was successfully done in all cases without any intra-operative complication.

Patients were followed up for 6 months to determine any post-op complication. Data was collected from all these patients, statistical analysis was done and results expressed as mean values with standard deviations, ranges and percentages. P-value < 0.05 was considered significant.

RESULTS

50 eyes of 40 patients were included in this study. Out of which, 16 (40%) were male and 24 (60%) were female. Right eye was involved in 30 cases (60%) and left one in 20 cases (40%). Average age was 54.3 ± 7.4 (range 48 – 65) years (table 1).

Mean pre-op IOP was 17.6 ± 2.3 (range 12 – 24.2) mm Hg with mean pre-op anterior chamber depth (ACD) of 2.1 ± 0.34 (range 1.6 – 2.6) mm and mean pre-op axial length (AL) of 20.6 ± 0.45 (range 19.5 – 22.2) mm (table 2).

Table 1: Demographic variables.

Demographic Variables		Study Population (n = 50)
Age:	Mean ± SD	54.3 ± 7.4 (range 48–65)
Gender:	Male/Female	40% (16)/60% (24)
Laterality:	Right/Left	60% (30)/40% (20)

Table 2: Results.

Variables	Findings (n = 50)
Pre-op IOP Mean ± SD	17.6 ± 2.3 (range 12 - 24.2) mmHg
Pre-op ACD Mean ± SD	2.1 ± 0.34 (range 1.6 - 2.6) mm
Pre-op AL Mean ± SD	20.6 ± 0.45 (range 19.5 - 22.2) mm

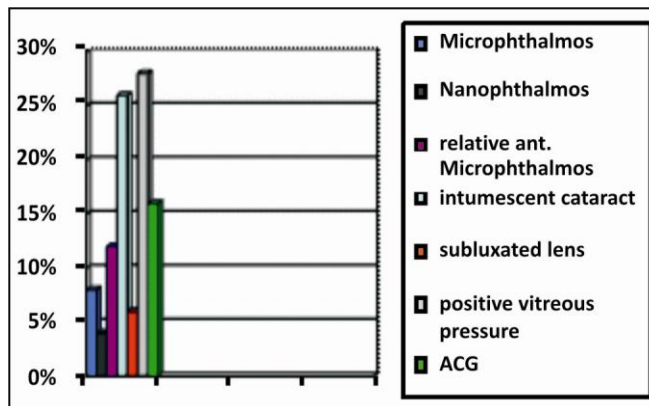


Figure 1: Types of patients.

There were 8 cases (16%) with angle closure glaucoma, 13 cases (26%) with intumescent cataract resulting in phacomorphic glaucoma, 3 cases (6%) of subluxated lens, 4 cases (8%) with simple microphthalmos, 2 cases (4%) with nanophthalmos, 6 cases (12%) with relative anterior microphthalmos and 14 cases (28%) with positive vitreous pressure (that was determined per-operatively when anterior chamber failed to deepen with viscoelastic substance) (Figure 1).

Vitreous tap was successful in 42 eyes (84%) on first attempt and in remaining eight eyes (16%), second attempt was required which made anterior chamber deep enough to allow phaco process to continue safely. Average volume of aspirated vitreous was 0.116 ± 0.03 (0.1 - 0.2) ml. The overall success rate was 100% with no intra-operative or post-operative

complications during 6 months follow up period (Figure 2, 3).

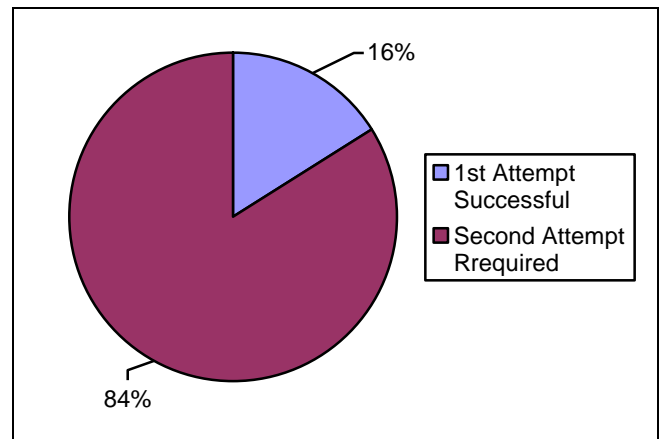


Figure 2: Success rate of vitreous tap.

DISCUSSION

Crowded anterior segment is a descriptive term, not a measurable entity. It is used to describe eyes with shallow anterior chambers due to short axial lengths, with intumescent cataract causing shallow chambers with normal axial length, narrow AC angle eyes or positive vitreous pressure where one would say, “I had difficulty in doing phaco in this patient because he had crowded anterior chamber”.

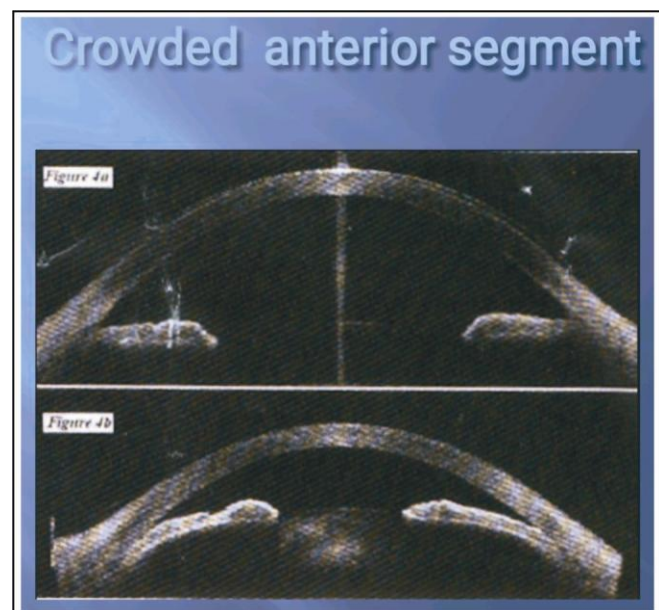


Fig. 3: a. Normal anterior segment, b. Crowded anterior segment.

Crowded anterior segment can be seen in many ophthalmic diseases. Microphthalmos^{10,11} is an eye with a short axial length. Microphthalmic eyes are divided into simple and complex ones. Simple microphthalmos has short axial length with no other ocular malformation. Complex Microphthalmos is an eye with a short AL and ocular anatomic malformations such as iris coloboma, chorioretinal coloboma, persistent fetal vasculature, and retinal dysplasia with normal scleral thickness.

Nanophthalmos^{12,13,14} is a rare condition in which the eye has a short axial length along with a small anterior segment and thickened choroid and sclera.

Relative anterior microphthalmos is an eye with a normal AL but a small anterior segment. These eyes have an axial length longer than 20.5 mm, but the anterior chamber depth (ACD) is equal to or less than 2.2 mm and the corneal diameter being shorter than 11.0 mm. It is more common than microphthalmos and nanophthalmos^{15,16}.

Phacomorphic glaucoma is the secondary angle-closure glaucoma due to intumescent cataract resulting in increased lens thickness, which can lead to pupillary block and angle closure¹⁷.

Positive vitreous pressure also occurs during cataract surgery and is associated with acute hypotony that causes forward displacement of the lens-iris diaphragm with shallowing of the anterior chamber resistant to reformation, repeated iris prolapse, that can lead to a cascade of intraoperative complications¹⁸.

Extreme care is required in all these patients. Proper preoperative evaluation allows better planning of the surgery to avoid complications. To reduce positive vitreous pressure, I/V infusion of mannitol 30-60 min prior to surgery was also recommended, but its use is limited due to its serious side effects. Pars plana vitrectomy also remained a choice for many surgeons to deepen the anterior chamber but it has some disadvantages. The fashioned sclerotomy may leak or require suturing. That is why using the small 23 or 25 gauge¹⁹ vitrectomy probe is preferred than using the conventional 20-gauge vitrectomy probe for this purpose, in addition to the advantage of higher cutting rates resulting in minimal retinal traction, but unfortunately most of the phacoemulsification systems incorporate low-cutting speed 20-gauge vitreous cutters²⁰.

The idea of using vitreous needle aspiration to manage positive vitreous pressure during surgery was

investigated previously in penetrating keratoplasty (PKP)²¹ and in triple procedure involving PKP, cataract extraction, and intraocular lens implantation²². The main fear of vitreous needle aspiration is inducing retinal traction with subsequent retinal tears, vitreous haemorrhage, or retinal detachment¹⁶. However, this technique was found to be safe without any complications. Earlier it was suggested that using a 23- to 26-gauge needle attached to an insulin syringe without the plunger allow passive removal of vitreous and avoids vitreous aspiration which may induce traction on the retina.

Ashraf et al²³ carried out a retrospective study including 26 eyes of 17 patients who underwent phacoemulsification in which vitreous tap was done using 27 gauge needle attached to 5 ml syringe in crowded eyes where viscoelastic substance failed to deepen the anterior chamber and results showed no complication related to vitreous tap, successful removal of vitreous with subsequent deepening of anterior chamber on first attempt in 26 eyes (100%).

In this study, we used 27-gauge needle, attached to 1 cc syringe and aspiration of 0.1 cc vitreous was done 4 mm from supero-temporal quadrant during cataract surgery in crowded anterior segment eyes that adequately deepened the anterior chamber. Thus, preventing damage to corneal endothelium, Descemet's membrane detachment, iris prolapse, capsulorhexis extension, Posterior capsular rent, vitreous haemorrhage and supra-choroidal haemorrhage without increasing the risk of retinal traction as aspirated fluid was minimal. Vitreous tap using needle aspiration is machine independent. It uses simple needles and syringes which are easily available in operation theatres. It is quite easy to perform, cost-effective and saves time without creating an extra wound while allowing a precise amount of vitreous to be removed for safe accomplishment of phacoemulsification in crowded anterior segment eyes.

CONCLUSION

A pars-plana vitreous tap makes the anterior chamber deep thus allowing every step of cataract surgery (capsulorhexis, phacoemulsification and IOL implantation) to be carried out safely and effectively in these high risky eyes without causing any corneal decompensation, capsulorhexis extension, PC rupture or supra-choroidal haemorrhage while keeping the advantages of a small incision.

Vitreous tap using 27-gauge needle is simple, safe, efficient and cost-effective technique for management of shallow anterior chambers.

Author's Affiliation

Dr. Irfan Qayyum Malik
Associate professor ophthalmology
Gujranwala Medical College

Dr. Hafiza Sadia Imtiaz
PGR
Gujranwala Medical College

Dr. Fazeela Shehzad
Associate professor Gynecology
Gujranwala Medical College

Role of Authors

Dr. Irfan Qayyum Malik
Study design, Manuscript writing, critical review.

Dr. Hafiza Sadia Imtiaz
Helped in data collection

Dr. Fazeela Shehzad
Helped in writing manuscript

REFERENCES

1. **Chang D.** Pars plana vitreous tap for phacoemulsification in the crowded eye. *J Cataract Refract Surg*, 2001; 27 (12): 1911-1914.
2. **Hoffman R, Vasavada A, Allen Q, Snyder M, Devgan U, Braga-Mele R.** Cataract surgery in the small eye. *J Cataract Refract Surg*, 2015; 41 (11): 2565-2575.
3. **Masket S.** Cataract surgical problem. *J Cataract Refract Surg*, 2006; 32 (6): 908.
4. **See J.** Phacoemulsification in angle closure glaucoma. *J Curr Glaucoma Pract*, 2009; 3 (1): 28-35.
5. **Khng C, Osher R.H.** Surgical options in the face of positive pressure. *J Cataract Refract Surg*, 2006; 32 (9): 1423-1425.
6. **Chalam K.V, Gupta S.K, Agarwal S, Shah V.A.** Sutureless limited vitrectomy for positive vitreous pressure in cataract surgery. *Ophthalmic Surg Lasers and Imaging Retina*, 2005; 36 (6): 518-522.
7. **Dada T, Kumar S, Gadia R, Aggarwal A, Gupta V, Sihota R.** Sutureless single-port transconjunctival pars plana limited vitrectomy combined with phacoemulsification for management of phacomorphic glaucoma. *J Cataract Refract Surg*, 2007; 33 (6): 951-954.
8. **Miura S, Ieki Y, Ogino K, Tanaka Y.** Primary phacoemulsification and aspiration combined with 25-gauge single-port vitrectomy for management of acute angle closure. *Eur J Ophthalmol*, 2008; 18 (3): 450-452.
9. **Wladis E.J, Gewirt M.B, Guo S.** Cataract surgery in the small adult eye. *Survey of Ophthalmology*, 2006; 51 (2): 153-161.
10. **Carifi G, Safa F, Aiello F, Baumann C, Maurino V.** Cataract surgery in small adult eyes. *Br J Ophthalmol* 2014; 98 (9): 1261-1265.
11. **Tailor R, Ng A, Murthy S.** Cataract Surgery in Patients with Nanophthalmos. *Ophthalmology*, 2014; 121 (2): e11.
12. **Day A, MacLaren R, Bunce C, Stevens J, Foster P.** Outcomes of phacoemulsification and intraocular lens implantation in microphthalmos and nanophthalmos. *J Cataract Refract Surg*, 2013; 39 (1): 87-96.
13. **Lemos J, Rodrigues P, Resende R, Menezes C, Gonçaves R, Coelho P.** Cataract surgery in patients with nanophthalmos: results and complications. *Eur J Ophthalmol*, 2015; 26 (2): 103-106.
14. **Steijns D, Bijlsma W, Van der Lelij A.** Cataract Surgery in Patients with Nanophthalmos. *Ophthalmology*, 2013; 120 (2): 266-270.
15. **Yuzbasioglu E, Artunay O, Agachan A, Bilen H.** Phacoemulsification in patients with nanophthalmos. *Can J Ophthalmol*, 2009; 44 (5): 534-539.
16. **B. Kaplowitz K.** An Evidence-Based Approach to Phacomorphic Glaucoma. *JCEO*, 2013; 04 (02).
17. **Chronopoulos A, Thumann G, Schutz J.** Positive vitreous pressure: Pathophysiology, complications, prevention, and management. *Surv Ophthalmol*, 2017; 62 (2): 127-133.
18. **Leng T, Moshfeghi D.** Valved 25-Gauge Cannula for Vitreous Tap and Injection. *Ophthalmic Surg, Lasers and Imaging Retina*, 2017; 48 (11): 916-917.
19. **Spirn M.** Comparison of 25, 23 and 20-gauge vitrectomy. *Curr Opin Ophthalmol*, 2009; 20 (3): 195-199.
20. **Gross R, Shaw E.** Management of Increased Vitreous Pressure during Penetrating Keratoplasty Using Pars Plana anterior Vitreous Aspiration. *Cornea*, 2002; 21 (4): 435-436.
21. **Vongthongsri A, Jakpawong W, Preechanon A, Lekhanont K, Chuck R.** Anterior Vitreous Tapping to Manage Positive Vitreous Pressure during Triple Procedures. *Ophthalmology*, 2005; 112 (5): 875-878.
22. **Sethi H, Dada T.** Pars plana vitreous tap in crowded eyes. *J Cataract Refract Surg*, 2002; 28 (11): 1897.
23. **Nossair A, Ewais W, Ali L.** Retrospective Study of Vitreous Tap Technique Using Needle Aspiration for Management of Shallow Anterior Chamber during Phacoemulsification. *J Ophthalmol*, 2017; 2017: 1-6.