

Visual Outcome and Complications of Boston Keratoprosthesis: An Experience from North West Pakistan

Ibrar Hussain

Pak J Ophthalmol 2017, Vol. 33, No. 3

.....
See end of article for
authors affiliations
.....

Correspondence to:
Ibrar Hussain
Department of Ophthalmology,
Khyber teaching hospital,
Peshawar, Pakistan
Email:dribrar@hotmail.com

Purpose: The Purpose of this study is to document the visual outcome and complications of Boston Keratoprosthesis implant in corneal blindness.

Study Design: Descriptive case series.

Place & Duration of Study: This study was performed at Khyber Teaching Hospital Peshawar from April 2009 to April 2016.

Material & Method: Nine eyes of 8 patients were included in the study. In all eyes preoperative visual acuity recorded and slit lamp examination performed. In each case status of anterior segment and diagnosis documented, B-scan performed and Boston keratoprosthesis implanted under general anesthesia. Postoperative visual acuity and complications documented during the course of follow up and data analyzed.

Results: Preoperative diagnoses of these patients include Steven Johnson Syndrome in 3 (33.3%) eyes, bomb blast injury in 3 (33.3%) eyes, healed corneal ulcers with failed corneal graft in 2 (22.2%) eyes and Peter anomaly in 1 (11.1%) eye. All the corneas were opaque and vascularized and preoperative visual acuity was perception of light only. In final follow up visual acuity was 20/200 in 2 (22.2%), 10/200 in 2 (44.4%), 3/200 in 1 (11.1%), perception of light in 3 (33.3%) and no perception of light in 1 (11.1%). Postoperative complications were retro-prosthetic membrane in 6(66.6%) eyes, glaucoma in 1 (11.1%) eye, device extrusion in 3 (33.3%), sterile keratolysis in 3 (33.3%), phthisis bulbi in 3 (33.3%), retinal detachment in 1 (11.1%) and endophthalmitis in 1 (11.1%) eye.

Conclusion: Type 1 Boston Keratoprosthesis implant still has poor prognosis in patients with SJS and severely traumatized eye e.g., bomb blast injuries and this is related mainly to preexisting bad eye condition.

Key Words: Artificial cornea, Boston Keratoprosthesis, Corneal blindness.

.....
Corneal blindness is the 2nd most common cause of blindness in the world¹. Standard way to treat corneal blindness is keratoplasty but there are several factors like severe dry eyes, corneal vascularization, etc which can lead to graft failure. In cases where there is repeated graft failure or primary graft is likely to fail, use of keratoprosthesis (KPro) is considered. The concept of using a keratoprosthesis in corneal blindness has been known for more than 200 years². Several groups have worked

for many years to develop a keratoprosthesis that could treat patients with corneal blindness having poor prognosis for penetrating keratoplasty^{3, 4}.

Recently it is gaining popularity due to its improved design with better visual outcome and relatively lesser complications. One of the most commonly used designs in recent year is "Boston keratoprosthesis". It consists of a mushroom shaped optical part and a fenestrated back plate. It is fitted in

the center of an 8.5mm donor corneal graft like a collar button. A titanium locking ring holds the back plate in place. Then this KPro laden graft is implanted in the recipient eye like traditional penetrating keratoplasty.

In 1974, Dohlman et al first reported results from implantation of a PMMA collar-button keratoprosthesis (KPro) in 36 patients⁵. Present study is designed to evaluate indications, visual outcome and complication of Boston KPro type I in North West Pakistan and to compare its results with other international reports.

MATERIAL AND METHODS

Nine eyes of eight patients were selected for Boston KPro implantation. Each patient underwent detailed slit lamp examination to assess the status of anterior segment. Intraocular pressure was taken on each eye and also B-scan ultrasound performed to assess the status of posterior segment. All of the nine Boston KPro type-I were obtained from Massachusetts Eye and Ear Infirmary, Boston, USA, and were implanted by the author (IH) at department of Ophthalmology, Khyber Teaching Hospital Peshawar, Pakistan. The power of KPro was calculated by the provider, using axial length of the eye, which we provided in "order form" of each case.

Surgical technique involved the following steps. An 8.5mm donor button was prepared from donor corneal graft. In patients whose own cornea was used to hold the KPro, there central 8.5mm cornea was excised using a trephine. The 8.5mm button of cornea was trephined in the centre using 3mm dermatological punch. The stem of the mushroom shaped optical part of the KPro passed through the central 3mm hole of the corneal button in such a way that upper flat part of

the KPro optic remained in convex (epithelial) and the stem protruded towards concave (endothelial) side of the corneal button.

The fenestrated plate was applied to the back of this button. A titanium ring was passed into the stem behind the plate to stabilize the whole complex. Later, under general anaesthesia, the patient's cornea was trephined with 8.5 mm trephine and corneal button removed. In three patients crystalline lens was removed to make the patients aphakic, while rest of the patients were already aphakic. Anterior vitrectomy was performed in all cases. Finally the KPro laden corneal button was implanted into patient's cornea like an ordinary penetrating keratoplasty, using 16 interrupted sutures with 10/0 nylon.

This is a prospective study, in which preoperative diagnosis, surface wetting and intraocular pressure were noted. Intraoperative complications and postoperative visual outcome and complications were also recorded. Patients were followed up from 6 to 18 months and visual acuity and complications were recorded on final visit.

Results obtained by analyzing data through SPSS (version 14).

RESULTS

Nine eyes of eight patients were included in the study. Seven (87.5.7%) patients were males and one (12.5%) was female. Average age of patients was 34.11 ± 15.47 years ranging between 12 & 60 years. Mean postoperative follow up duration of all patients was 13.85 months (range 6 - 18 months), while one patient missed initial follow up and reappeared after 8 months. Data of all nine patients included in this study is given in table.

Table 1: Complete data of all 9 patients included in the study.

Patients	Age in Years	Diagnosis	Preop. VA	VA at Last follow up	Complications
1	35	SJS	PL	PL	RPM Sterile keratolysis Implant Extrusion Phthisis bulbi
2	22	BBI	PL	PL	RPM Endophthalmitis Implant Extrusion Phthisis

3	35	SJS	PL	PL	Sterile keratolysis Phthisis bulbi
4	54	Healed corneal ulcer with failed corneal graft	PL	20/200	RPM
5	62	Healed corneal ulcer with failed corneal graft	PL	20/200	Glaucoma RPM
6	25	BBI	PL	10/200	RPM
7	32	BBI	PL	10/200	RPM Localized RD
8	12	Peter anomaly	PL	3/200	
9	30	SJS	PL	No PL	Sterile keratolysis Implant Extrusion Phthisis bulbi
Mean Age	34.11				

(BBI=Bomb blast injury, PL=Perception of light, RD=Retinal detachment, RPM= Retroprosthetic membrane, SJS= Steven Johnson Syndrome)

Primary corneal pathologies include SJS 3(33.3%) eyes BBI 3(33.3%) eyes, healed corneal ulcer with failed corneal graft 2(22.22) eyes and Peter anomaly one (11.1%) eye.

Six (66.6%) eyes had undergone one or more ocular surgeries before implantation of the KPro. These include corneal repair in 3(33.3%) eyes and keratoplasty in 6(66.6) eyes. Three eyes with BBI underwent corneo-scleral repair followed by keratoplasty later on. In 3(33.3) eyes the Boston KPro was implanted with no prior keratoplasty (One eye of Peter anomaly and two eyes of SJS). Out of the nine KPro, 4(44.4%) were implanted in their own corneas

and 5(55.5%) in donor corneas. Intraoperative complication included spill over of blood from cut edge of patient's vascularised cornea in anterior chamber and the vitreous in all (100%) cases. In 5(55.5%) eyes anterior segment was found deformed due to adhesions of iris and pupil to back of cornea. Six patients (66.6%) were already aphakic while in 3(33.3%) cases lens extraction was also performed during surgery.

Preoperative visual acuity was only perception of light (PL) with good projection in all eyes.

Postoperative improvement in visual acuity at last follow up is shown in a table 2.

Table 2: Preoperative and Postoperative visual acuity in all patients.

Visual Acuity	Number of Eyes (%)					
	All Cases (Preop)	SJS (Last Follow up)	BBI (Last Follow up)	Corneal Ulcer (Last Follow up)	Peter Anomaly (Last Follow up)	All Cases (Last Follow up)
NoPL	0	1	0	0	0	1
PL	9	2	1	0	0	3
3/200	0	0	0	0	1	1
10/200	0	0	2	0	0	2
20/200	0	0	0	2	0	2
Total	9 (100%)	3 (33.3%)	3 (33.3%)	2 (22.2%)	1 (11.1%)	9 (100%)

(No PL=No perception of light, PL= Perception of light)

Table 3: Postoperative Complications.

	Retro Prosthetic Membrane	Sterile Keratolysis	Implant Extrusion	Phthisis Bulbi	Endophthalmitis	Glaucoma	Retinal Detachment
Bomb Blast Injury	3	0	1	1	1	0	1
Healed Corneal Ulcer	2	0	0	0	0	1	0
Peter Anomaly	0	0	0	0	0	0	0
Steven Johnson Syndrome	1	3	2	3	0	0	0
Total	6	3	3	4	1	1	1

Note: Total number of eyes in this table is more than 9, because most of the eyes had more than one complication.

The most common complication was retro-prosthetic membrane (RPM) formation which occurred in 6 eyes. One eye developed endophthalmitis and became NoPL (No perception of light). Sterile keratolysis occurred in all 3 eyes with SJS, which led to extrusion of the implant in 2 eyes and ultimately the eyes became phthisic. The third eye with SJS also became phthisic. One eye with BBI developed localized retinal detachment. All complications with their relation to primary ocular disease are shown in Table 3.

DISCUSSION

All the nine cases included in our study were hopeless cases with preoperative visual acuity of PL (Perception of light) only. Three eyes had bomb blast injuries (BBI) and had undergone corneo-scleral repairs. Three other cases were of Steven Johnson Syndrome (SJS), with severe dry eyes (Fig.1). All the nine eyes had severely vascularized and totally opaque corneae.

Out of the three cases of BBI, only two retained navigational vision (finger counting close to eye) till last follow up visit. One of these two had posterior pole preretinal fibrosis and other one had localized retinal detachment. Third patient developed corneal melting followed by endophthalmitis and extrusion of the implant. We could not find any study in literature

pertaining to the use of Boston KPro in eyes with BBI. However, Harissic- Dagher and Dohlman in their paper "The Boston keratoprosthesis in severe ocular trauma" mentioned 6 cases of mechanical trauma out of their total 30 studied cases. In their research anatomic success was achieved in 5 out of 6 mechanically traumatized eyes⁶.

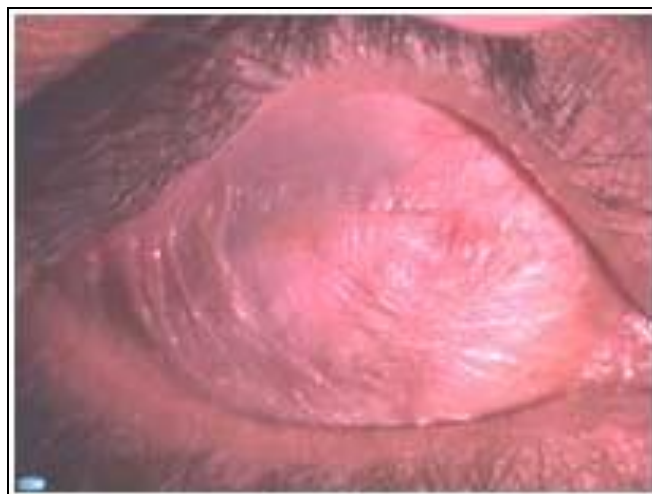

Fig. 1: Severe dry ocular surface in Steven Johnson Syndrome.

Three eyes with SJS also had poor outcome (Fig.2).

One eye retained 20/200 vision in first year but after that the cornea started melting and the KPro extruded. Other eye of the same patient became phthisic within two months of the KPro implantation and vision did not improve from PL. Third patient

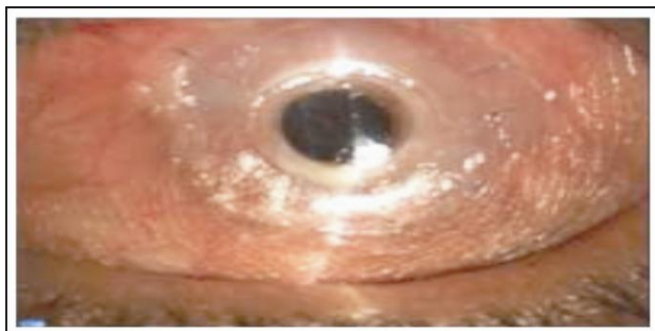

Fig. 2: Boston KPro in Steven Johnson Syndrome

initially obtained 20/60 vision after one week of surgery but after that it started deteriorating and cornea started melting. Within a month the KPro extruded and eye became phthisic. These three eyes had severe dry ocular surface and it is this dryness that determines the retention rate of the device. According to a study from Massachusetts eye and ear infirmary by Yaghouti F and colleagues, the outcome of KPro surgery is worse in patients with SJS⁷. In this condition chronic inflammation around the KPro makes the tissue vulnerable to necrosis, melting, leakage and infection. In this study⁷ it is demonstrated that 33% of eyes with SJS maintained 6/60 (20/200) vision for 2 years. This figure was minimal as compared to chemical burns (64%), ocular cicatricial pemphegoid (72%) and non cicatricial causes (83%). Another study from same institute mentions the use of corticosteroids (even in low doses) in SJS causes tissue melt and perforation⁸. In contrast, in a study by Sayegle RR et al on fifteen patients with SJS, there was no KPro extrusion or endophthalmitis⁹. In this study only six eyes underwent type-1 KPro while the rest underwent type-2 KPro implantation.

Two of our cases were of healed corneal ulcer with corneal vascularization. Both of these had undergone penetrating keratoplasty once, but failed. Both of them retained the KPro till last follow up. Visual acuity improved to 10/200 and 20/200 after 3 months but reduced again at last follow up. One patient developed post-prosthetic membrane and other developed glaucomatous optic atrophy. Both these

complications are known complications in eyes with type 1KPro.

One of the patient in this series was a 12 years old girl with Peter anomaly. She had nystagmus since early childhood. In initial postoperative period, there was no improvement in vision but after 4 months she had developed navigational vision and the KPro was retained. Use of Boston KPro is gaining popularity in pediatric population. According to a study by Aquavella JV and colleagues the Boston KPro establishes and maintains a clear pathway and does not prejudice the management of glaucoma or retinopathy in children¹⁰.

COMPLICATIONS

Most common complication in our cases was retroprosthetic membrane (RPM) formation in 6(66.6%) cases. These membranes were thick and vascularized. Only in two cases membranectomy was possible with Nd-Yag laser, while in other four cases the membrane was too thick to respond to Nd-Yag laser. In a study by Shihadeh and Mohidat on 20 eyes, the frequency of RMP formation was 45% and all of them treated successfully with Nd-Yag laser¹¹. Its frequency is 43% in a study by Bradley et al¹², 25% in a multicentre study by Zerbe et al¹³ while 27% - 35% in prior published data⁷. According to one hypothesis RPM formation may be caused by inflammatory cells reacting to polymethyl methacrylate material of KPro¹⁴. Another theory about RPM formation is mentioned by Colby,^[15] according to which the histopathological fibrous structure of RPM originates from host stromal cells that migrate through gaps in the graft host tissue junction. In our study highest rate of RPM could be due to excessive inflammation in cases with SJS and BBI.

Glaucoma is another common and the most important vision threatening complication after Boston KPro implant¹⁶. One patient (11.1%) of our series developed glaucoma after surgery. This patient disappeared and reappeared after about 8 months with glaucomatous optic atrophy and high IOP detected digitally. In many studies glaucoma has been mentioned as a postoperative complication with different frequencies. Zerbe et al mentioned 15 % of their cases had high IOP after surgery¹³. Shihadeh et al mentioned it in 25% eyes¹¹, and Chew et al indicated in 35% eyes¹⁴. In addition many patients have preexisting glaucoma. Previous studies from multiple institutes have mentioned prevalence between 36 and

76%^{13,14,17-19}. This is because eyes that need Boston KPro have undergone multiple anterior segment surgeries or have diseases that cause intraocular inflammation and need to use steroid²⁰. "Steroids response ocular hypertension" is prevalent among these patients which can contribute to development of glaucoma²¹. Glaucoma drainage devices are the mainstay for long term control of glaucoma but these have their own complications which can cause significant visual loss²².

Endophthalmitis is another damaging complication following Boston KPro implantation. One case of our series developed severe endophthalmitis two months after KPro implantation and that led to extrusion of the implant and loss of vision to NoPL (no perception of light). This was an eye with BBI and did not respond to intravitreal vancomycin. Robert and colleagues reviewed endophthalmitis following Boston KPro in literature from 2001 to 2011 and found that its prevalence was 5.4% and gram positive bacteria are the most common agents responsible²³. Rarely fungal endophthalmitis can also occur and its rate is higher in patients using vancomycin prophylaxis and patients wearing therapeutic contact lens²⁴.

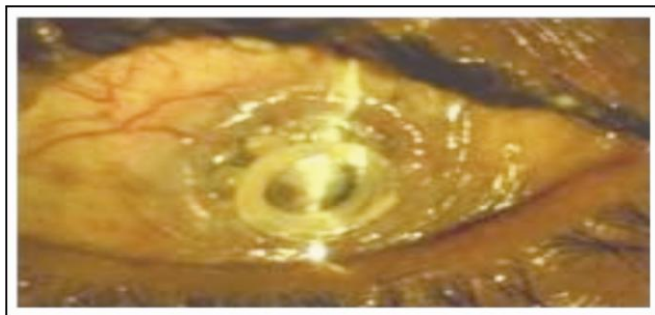


Fig. 3: Sterile Keratolysis in eye with Boston KPro

Three (33%) implants of our case series were extruded. Causes of extrusion were endophthalmitis in one case and sterile keratolysis (Fig.3) in 2 cases of SJ syndrome. In a study by Ciolino and colleagues on 300 eyes where Boston KPro type 1 was implanted, 21(7%) eyes failed to retain the device²⁵. In this study causes of extrusion include sterile keratolysis, infection and dense RPM. A high figure of 33% extrusion in our series is due to selection of high risk cases for KPro implant i.e., SJ syndrome and BBI.

CONCLUSION

Type 1 Boston Keratoprosthesis implant still has poor prognosis in patients with SJS and severely traumatized eye like bomb blast injuries and this is mainly due to the preexisting bad eye condition.

Author's Affiliation

Prof. Dr. Ibrar Hussain
Department of Ophthalmology,
Khyber teaching hospital, Peshawar, Pakistan.

Role of Author

Prof. Ibrar Hussain
All work including basic idea, data collection, result compilation, references collection and article writing.

REFERENCES

1. **John PW, Srinivasan M, Madan PU.** Corneal blindness: a global perspective. *Bull World Health Organ*, 2001; 79: 214-221.
2. **Pellier de Quengsy G.** *Precis au cours d' operations sur la chirurgie des yeux.* Paris: Didot, 1789.
3. **Barber JC.** Keratoprosthesis: past and present. *Int Ophthalmol Clin.* 1988; 28: 103-9.
4. **Hicks CR, Fitton JH, Chirila TV, Crawford GJ, Constable IJ.** Keratoprosthesis: advancing toward a true artificial cornea. *Surv Ophthalmol.* 1997; 42: 175-89.
5. **Dohlman CH, Schneider H, Doane MG.** Prosthokeratoplasty. *Am J ophthalmol.* 1974; 77: 694-700.
6. **Harissi - Dagher M, Dohlman CH.** The Boston Keratoprosthesis in severe ocular trauma. *Can J Ophthalmol.* 2008, 43: 165-169.
7. **Yaghouti F, Nouri M, Abad JC, Power WJ, Doane MG, Dohlman CH.** Keratoprosthesis: Preoperative Prognostic Categories. *Cornea*, 2001; 20: 19-23.
8. **Dohlman JG, Foster CS and Dohlman CH.** Boston Keratoprosthesis in Steven-Johnson Syndrome: A case of using infliximab to prevent tissue necrosis. *Digital journal of ophthalmology*, 2009: 15.
9. **Sayegh RR, Ang LPK, Foster CS, Dohlman CH.** The Boston Keratoprosthesis in Steven - Johnson Syndrome. *Invest Ophthalmol Vis Sci.* 2010; 51: 857-863.
10. **Aquavella JV, Gearinger MD, Akpek EK, McCormick GJ.** Pediatric keratoprosthesis. *Ophthalmology*, 2007; 114: 989-94.
11. **Shihadeh WA, Mohidat HM.** Outcomes of the Boston Keratoprosthesis in Jordan. *Middle East Afr J Ophthalmol.* 2012; 19: 97-100.
12. **Bradley JC, Hernandez EG, Schwab IR, Mannis MJ.** Boston type 1 keratoprosthesis: The University of California Davis Experience. *Cornea*, 2009; 28: 321-7.

13. **Zerbe BL, Belin MW, Ciolino JB.** Result from the Multicenter Boston Type 1 Keratoprosthesis Study. *Ophthalmology*, 2006; 113: 1779-85.
14. **Chew HF, Ayres BD, Hammersmith KM, Rapuano CJ, Laibson PR, Myers JS et al.** Boston keratoprosthesis outcomes and complications. *Cornea*, 2009; 28: 989-96.
15. **K Colby.** Boston keratoprosthesis in 2012: Preventing complication and optimizing outcomes. *Acta Ophthalmologica* 2012; 90: 0.
16. **Vora GK, Colby KA.** Management of Glaucoma Following Boston Keratoprosthesis. *European Ophthalmic Review*, 2012; 6: 214-7.
17. **Ma JJ, Graney JM, Dohlman CH.** Repeat penetrating keratoplasty versus the Boston Keratoprosthesis in graft failure. *Int Ophthalmol Clin.* 2005; 45: 49-59.
18. **Netland PA, Terada H, Dohlman CH.** Glaucoma associated with keratoprosthesis. *Ophthalmology*, 1998; 105: 751-7.
19. **Greiner MA, Li JY and Mannis MJ.** Longer-term vision outcomes and complications with the Boston type 1 Keratoprosthesis and the University of California, Davis, *Ophthalmology*, 2011; 118: 1543-50.
20. **Khan BF, Harissi DM, Khan DM, Dohlman CH.** Advances in Boston keratoprosthesis: enhancing retention and prevention of infection and inflammation, *Int Ophthalmol Clin.* 2007; 47: 61-71.
21. **Banitt M.** Evaluation and management of glaucoma after keratoprosthesis, *Curr Opin Ophthalmol.* 2011; 22: 133-6.
22. **Li JY, Greiner MA, James D, Brandt, Lim MC, Mannis MJ.** Long-term Complications Associated with Glaucoma Drainage Devices and Boston Keratoprosthesis. *Am J Ophthalmol.* 2011; 152: 204-218.
23. **Robert MC, Moussally K, Harissi Dagher M.** Review of endophthalmitis following Boston keratoprosthesis type 1. *Br J Ophthalmol.* 2012; 96: 776-780.
24. **Barnes SD; Dohlman CH and Durand ML.** Fungal Colonization and infection in Boston Keratoprosthesis. *Cornea*, 2007; 26: 9-15.
25. **Ciolino JB, Belin MW, Todani A, Al-Arfaj K, Rudnisky CJ.** Retention of the Boston Keratoprosthesis Type 1: Multicenter Study Results. *Ophthalmology*, 2013; 20: 1195-1200.