

Choroidal Melanoma, A Rare Condition in Asians: A Case Report

Irshad Haider, Saqeeba Fazal Khatri, Shareef Hashmani

Pak J Ophthalmol 2015, Vol. 31 No. 1

See end of article for authors affiliations

Correspondence to:
IrshadHaider
Consultant Surgeon
Hashmanis Hospital
Karachi
irshad1998@hotmail.com

A 30 year old male patient presented with chief complains of uni-ocular decreased vision. His history was not significant for any kind of intraocular tumor or mass and this case did not exhibit typical features of choroidal melanoma. A combination of laboratory testing and anatomical assessment were used in making diagnosis; which resulted in no extra ocular extension and absence of metastasizing cells elsewhere in the body. It then led to management by enucleating the eye and its histopathological examination confirmed pigmented malignant melanoma arising from choroid.

Key words: Choroidal melanoma, UV radiations, enucleation.

Melanoma refers to a dark – pigmented, malignant, frequently widely metastasizing tumor arising from a melanocyte.

Choroidal melanoma, as the name suggests, is a tumor that arises from the vascular layer of the eye choroid. This arises from the melanocytes (pigment cells) that dwell within the uvea which is responsible for eye’s color. These cells are not related to retinal pigmented epithelium cells.

Choroidal melanoma is the most common primary intraocular malignancy with an incidence of only six cases per million of population per year in USA It is more frequently seen in adults than children. Some studies suggest its association with male gender.¹⁻³

There are some etiological factors responsible for its occurrence such as race or ethnicity, and various studies suggest sunlight as a predisposing factor. Among these factors race seems more responsible, as evident from the fact that Choroidal melanoma is found to be least common in Asians and rate of its occurrence is high in Whites, Casusasains, and blond and light skin toned people.²⁻⁴

The environmental risk factor proposed by studies is sunlight because it is responsible for skin melanomas; however, the rate of ocular melanoma is

not increasing and is less likely to occur in non-whites unlike the type of melanoma related to skin.¹

Management of melanoma depends upon several clinical factors .options include observation, photocoagulation, transpupillary thermotherapy, local resection, enucleation and various combinations of these methods. The two most frequently employed treatment methods are enucleation and plaque brachytherapy.

Plaque brachytherapy is the most common conservative treatment used in the management of choroidal melanomas followed by charged-particle radiotherapy. Currently, I-125 and Ruthenium-106 (Ru-106) sources are widely used worldwide.⁵ it is also associated with radiation related complications like cataract formation, vitreous haemorrhage, dry eye, keratitis etc.

We, hereby, report a clinical case study of Choroidalmelonama witnessed in a 30 year old Pakistani citizen.

CASE REPORT

A thirty – years – old resident of Liyari came through OPD on April 9, 2014 with the complaint of vision loss in the right eye. His visual acuity recorded that day was, counting fingers in right eye while with his left

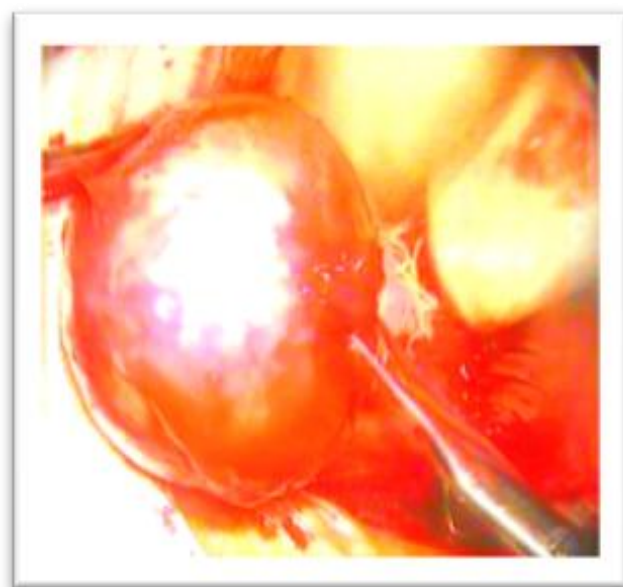
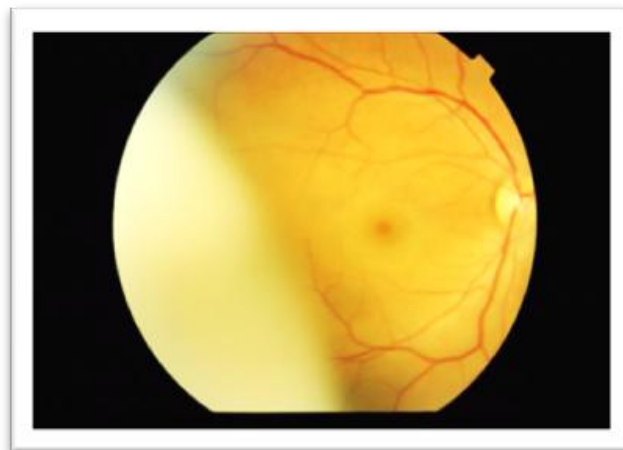
eye he was able to read 6/12. The patient had cataract in his right eye.

The patient underwent few clinical examinations including fundus photography, ultrasound (B-scan) and C.T scan.

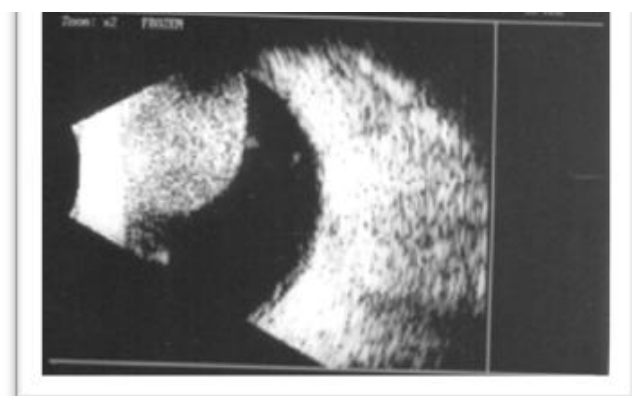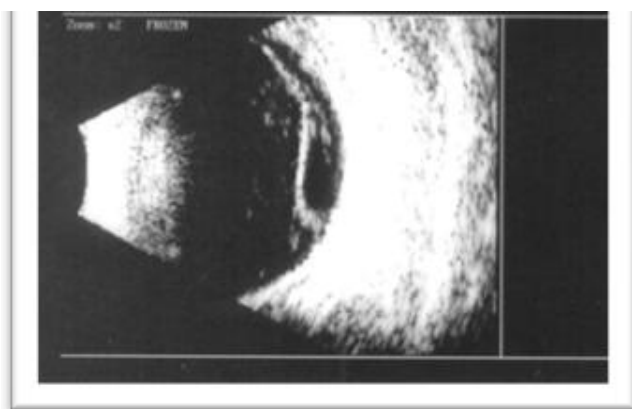
The fundus picture of his right eye showed an abnormal shadow appearing at the temporal side, whereas, his left eye was all normal. His B-scan of right eye showed signs of probable occurrence of tumor/mass. (But it did not show typical features of Choroidal melanoma). Which are an acoustically silent zone within the melanoma, choroidal excavation and shadowing in the orbit.

For visualizing the extra-ocular extension and differentiating retinal or choroidal mass, CT scan was performed which did not provide any evidence of extra-ocular extension.

Further medical workup was carried out including chest X-ray, LFT'S and blood CP, the impression by then was that the patient had choroidal melanoma with no metastasis in body elsewhere while considering differential diagnosis of choroidal navus,



Eye was enucleated with optic nerve intact.



choroidal detachment, intra ocular foreign body and choroidalosteoma; for confirming the diagnosis the eye was enucleated and was sent to histopathological analysis which reported a malignant tumor (1.3*1.5cm) attached to the side wall of choroid. Thus, the report concluded that a spindle cell pigmented malignant melanoma arising in choroidal layer.

For further investigations, fundus pictures were taken which showed a shadow appearing at the temporal side.

DISCUSSION

Choroidalmelanoma is a malignant primary type of intraocular tumor but it occurs very rarely among Asians. It is more commonly found in Whites, White-

Hispanics and Caucasians as compared to black skin-pigmented people and Asians.⁶

“The annual age-adjusted incidence (per million population) of uveal melanoma was 0.31 (black), 0.38 (Asian), 1.67 (Hispanic), and 6.02 (non-Hispanic white)”. However, the difference between the ratios of Asian versus black people was unremarkable.⁷

Few studies also suggest that its occurrence depends upon age group; the age group more prone to it includes people between 40 - 60 years of age. Though it tends to happen very rarely among Asians, but those unfortunate ones are young adults.^{8,9}

A research conducted by Biswas reported choroidal melanoma is seen in young Asians only and the ratio of male susceptibility is higher than females¹⁰.

However, the mystery for this disease occurring in Asians is still unrevealed. Some researches report it is more frequently seen in males and the pattern observed is usually unilateral.

Although the pathogenesis is still unclear but the probable cause seems to be UV radiations, exposure to sun light, which is also responsible for cutaneous melanoma as both types have similar cells of origin that is melanocyte.¹¹

A research published in Cancer Causes and Control described the occupational exposure of solar and artificial UV rays as possible factors responsible for choroidal melanoma, with the emphasis upon artificial UV rays. It stated that there is excessive risk of its occurrence among welders.¹² There is also a close relation between light colored irises and ultraviolet exposures, eyes with blue irises followed by green and hazel ones are at greater risk.¹³

Pakistan Journal of Ophthalmology published a case study of a Pakistani citizen that described the correlation of ocular melanocytosis which could ultimately lead to choroidal melanoma.¹⁴

Choroidal melanoma has typical characteristics that include dome or mushroom shaped pigmented mass with orange pigment that might or might not be associated with partial or total retinal detachment. Ultrasonography shows acoustic hallowing and choroidal excavation.^{15, 16}

Despite having these presentations at the fundus, the patient is sometimes unaware of the changes being taken place in his eye and this happened in the case we have reported. The patient came for eye examination only with the complaint of decreased vision in his right eye. Further detailed examinations

revealed presence of tumor but it did not show typical features with no pigmented mushroom or domed shaped mass and internal acoustic hallowing or excavation being commonly found in ultrasound (B-scan) reports.

RECOMMENDATIONS

Choroidal melanoma is a uveal pathology that shows few common associations with races and ethnicities. However, being rare among Asians, it can engender sight and life threatening problems. Its pathogenesis regarding light colored irises and UV rays is still a controversial issue but people should be made aware to take measures in beforehand to prevent this hazardous complication when exposed to UV rays during work time. Wearing sun shades regularly during outdoors and going for annual eye examination can help in prevention and early diagnosis of this condition.

Author's Affiliation

Dr. Irshad Haider
Consultant Surgeon
Hashmanis Hospital, Karachi

Saqeeba Fazal Khatri
BS Ophthalmic Technology
DUHS
Ophthalmic Technologist
Civil Hospital Karachi

Dr.. Shareef Hashmani
Consultant Surgeon
Hashmanis Hospital, Karachi

REFERENCES

1. **Egan KM, Johanna M.** Seddon, Robert J. Glynn, Evangelos S. Gragoudas. Epidemiologic aspects of uveal melanoma. *Survey of Ophthalmology*.1998; 32: 239-251.
2. **Singh AD, Bertil E. Damato BE.** Jacob Peer, A. Linn Murphee, D. Perry. *Essentials of Ophthalmic Oncology* 1st edition. Slack Incorporated; 2009.
3. **Jack J kanski,** clinical ophthalmology 6th edition. Elsevier health sciences; 2007.
4. **Singh AD, Rennie IG, Seregard S, Giblin M, McKenzie J.** Sunlight exposure and pathogenesis of uveal melanoma, *survey of ophthalmology*, 2004; 49: 419-28.
5. **Augsburger JJ, Shields JA.** Cataract surgery following cobalt 60 plaque radiotherapy for posterior uveal malignant melanoma, *ophthalmology* 1985; 92 (6): 815-822.

6. **Margo CE, Mulla Z, Billiris K.** Incidence of surgically treated uveal melanoma by race and ethnicity, *Ophthalmology*. 1997; 105: 1087-90.
7. **Hu DN, Yu GP, McCormick SA, Schneider S, Finger PT.** Population-Based Incidence of Uveal Melanoma in Various Races and Ethnic Groups. *American J Ophthalmol*. 2005; 140: 612.e1-612.e8.
8. **Biswas J, Kabra S, Krishnakumar S, Shanmugam MP.** Clinical and histopathological characteristics of uveal melanoma in Asian Indians: A study of 103 patients. *Indian j Ophthalmol*. 2004; 52: 41-4.
9. **Dhupper M, Biswas J, Gopal L, KumarSK, Vikas Khetan.** Clinicopathological correlation of choroidal melanoma in Indian population: A study of 113 cases. *Oman J Ophthalmol*. 2012; 5: 42-5.
10. The collaborative ocular melanoma study (COMS) randomized trial of pre-enucleation radiation of large choroidal melanoma. Characteristics of patients enrolled and not enrolled. COMS report No.9. *Am J Ophthalmol*. 1998; 125: 767-78.
11. **Tucker MA, Shields JA, Hartge P, Augsburger J, Hoover RN, Fraumeni JF.** Sunlight Exposure as Risk Factor for Intraocular Malignant Melanoma. *N Engl J Med*. 1985; 313: 789-92.
12. **Guénel P, Laforest L, Cyr D, Févotte J, Sabroe S, Dufour C, Lutz JM, Lyngge E.** Occupational risk factors, ultraviolet radiation, and ocular melanoma: a case-control study in France. *Cancer causes and control*, 2001; 12: 451-9.
13. **Schmidt - Pokrzywniak A, Jöckel KH, Bornfeld N, Sauerwein W, Stang A.** Positive Interaction Between Light Iris Color and Ultraviolet Radiation in Relation to the Risk of Uveal Melanoma: A Case-Control Study, *Ophthalmology*, 2009; 116: 340-8.
14. **Khan MT, Jan S, Hussain Z, Karim S, Khalid MK, Mohammad L.** Choroidal Melanoma in Ocular Melanocytosis: a case report. *Pak J Ophthalmol*. 2010; 26: 100-3.
15. Choroidal-melanoma, eye cancer network available from: <http://www.eyecancer.com/conditions/3/choroidal-melanoma>. Feb. 2014.
16. **Van Beek JGM, Koopmans AE, Verdijk MR, Naus NC, Klein AD, Kilic E.** Diagnosis, Histopathologic and Genetic Classification of Uveal Melanoma in: Guy Huynh Thien Duc, editor, *Melanoma - From Early Detection to Treatment*, Intech; 2013.